

Algorithm for the Diagnostic & Therapeutic Management of Tinnitus

TRI Tinnitus Clinic Network

Biesinger E, Del Bo L, De Ridder D, Goodey R, Herraiz C, Kleinjung T, Lainez JM, Landgrebe M, Langguth B, Londero A, Paolino M, Questier B, Sanchez T, Searchfield G (in alphabetical order)

The information contained herein is based on careful literature research, performed in August 2008 and further updated since then.

If specific diagnostic or therapeutic procedures are not mentioned, no clear evidence for their use has been found. ► [Evidence Levels](#)

This flowchart should not be considered as a "final version" but rather as "work in progress". It is intended to be a "living document" and thus the quality and actuality of the flowchart will depend on your feedback. Please send your comments and suggestions to the following e-mail address:

info@tinnitusresearch.org.

The authors will be very grateful for all kinds of feedback.

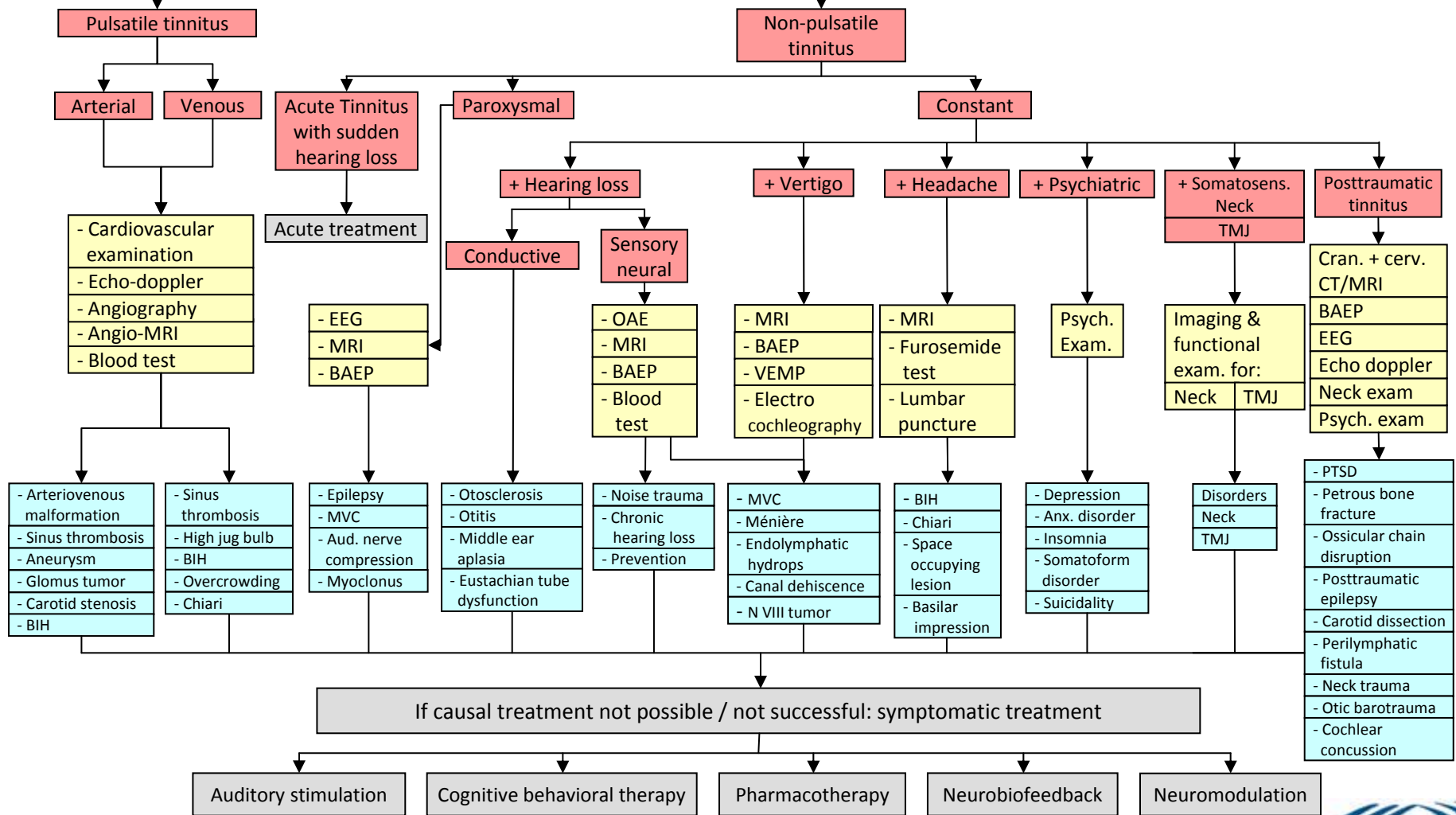
We hope that the TRI Flowchart for Patient Management will contribute to a better diagnosis and treatment of the many tinnitus patients worldwide, who seek help.

► [Start Flowchart](#)

No responsibility is assumed for any injury and/or damage to persons or property as a matter of product liability, negligence or otherwise, or from any use or operation of any methods, products, instructions or ideas contained in the material herein. Because of rapid advances in the medical sciences, in particular, independent verification of diagnoses and treatment should be made.

Specialized neuro-/otologist

History Self-performed questionnaires - Tinnitus Handicap Inventory - Tinnitus Questionnaire - Case History Questionnaire - Tinnitus Severity Grading (E.Biesinger)	+	Clinical examination - Otoscopy - Cranio-mandibular & neck examination - Auscultations	+	Audiological measurements - Audiometry - Psychophysical measurements - Tympanometry - Tubal impedance-manometry - Distortion product OAE
--	---	--	---	--



COUNSELLING

Abbreviations: BAEP = Brainstem auditory evoked potential, BIH = Benign intracranial hypertension, MVC = Microvascular compression, OAE = Otoacoustic emissions, PTSD = Posttraumatic stress disorder, SOL = Space occupying lesion, TMJ = Temporomandibular joint, VEMP = Vestibular evoked myogenic potential



Evidence Levels

- Level I: Evidence obtained from at least one properly designed randomized controlled trial.
- Level II-1: Evidence obtained from well-designed controlled trials without randomization.
- Level II-2: Evidence obtained from well-designed cohort or case-control analytic studies, preferably from more than one center or research group.
- Level II-3: Evidence obtained from multiple time series with or without the intervention. Dramatic results in uncontrolled trials might also be regarded as this type of evidence.
- Level III: Opinions of respected authorities, based on clinical experience, descriptive studies, or reports of expert committees.

Guirguis-Blake J et al (2007) [Current processes of the U.S. Preventive Services Task Force: refining evidence-based recommendation development](#). Ann Intern Med 2007 Jul 17;147(2):117-22



Questionnaires & History

Indication and short description

- Taking a case history is essential in all tinnitus patients. Items, that should be assessed, were agreed in a consensus at the first TRI meeting in Regensburg 2006 (document available at ► www.tinnitusresearch.org).
- For assessment of tinnitus severity and psychiatric comorbidity (depression, anxiety) standardized questionnaires should be used.

Diagnostic value

- A detailed patient history is essential for differential diagnosis.
- Tinnitus Questionnaires help to identify tinnitus severity and urgency of treatment, however limitations should be considered

Literature

Langguth et al (2007) [Consensus for patient assessment and outcome measurement](#). Prog Brain Res. 166:525-36



Clinical otorhinolaryngological examination

Indication

All tinnitus patients should be clinically examined by a specialised medical doctor

Short description

- Otoscopy/Microscopy: external auditory canal diseases, integrity of tympanic membrane, infections, middle ear effusion, chronic otitis media, cholesteatoma should be ruled out. If pulsatile tinnitus, see for effusion or vascular mass in middle ear (glomus). Check out movement of TM while breathing (patulous Eustachian tube)
- Rhinoscopy, oropharyngoscopy is highly recommended in all patients. Consider flexible or rigid endoscopy in some cases to rule out a nasopharyngeal mass
- Neck digital examination to rule out compressive masses
- Examination of cranial nerves (associated lesions)
- Tuning fork testing, vestibular assessment

Diagnostic value

Identifying abnormalities of the cochleovestibular system and the Head and Neck, which can present tinnitus as primary complaint

Literature

Snow JB (2004) [Tinnitus – Theory and Management](#). BC Decker Inc London, Hamilton (chap. 15)



Clinical examination - Auscultations

Indication

Pulsatile tinnitus

Short description

- Auscultation of the neck, both sides
- Auscultation of the neck after pressure to the jugular vein (if possible with ultrasound control)
- Auscultation of the area surrounding the pinna (mastoid area, temporal area, temporomandibular joint area)
- Auscultation of the orbicular area

Diagnostic value

- Murmurs in the neck could be related to carotid diseases.
- Murmurs in the temporal or mastoid area could be related to arteriovenous fistula or malformation
- Murmurs in the orbital region could be related to carotid-cavernous fistulas

Literature

Sismanis A (2003) [Pulsatile tinnitus](#). Otolaryngol Clin North Am. Apr;36(2):389-402, viii. Review



Audiological measurements

The Audiological assessment is based on the following exams:

- ▶ Pure Tone Audiometrical measurements
- ▶ Psychophysical audiometrical measurements (Tinnitus matching)
- ▶ Tympanometry, stapedius reflex
- ▶ Tubal impedance-manometry
- ▶ Distortion Product Otoacoustic Emission DPOAE

Literature

Snow JB (2004) Tinnitus – Theory and Management. BC Decker Inc
London, Hamilton (chap. 16)

Audiological measurements: Audiometry

Audiometrical measurements

Pure tone audiometry 125-16.000 Hz in audiometric boot

Indication

- Standard tests used to detect hearing problems in middle and inner ear

Diagnostic value

- Useful for DD of different forms of hearing pathologies
- Useful in counseling
- Potentially useful in monitoring outcomes
- Mandatory in setting hearing aids

Literature

JA Henry, MB Meikle (2000) [Psychoacoustic measures of tinnitus.](#)

J Am Acad Audiol. 2000 Mar;11(3):138-55.

R Tyler et al. (2008) American Journal of Audiology,

Snow JB (2004) [Tinnitus – Theory and Management.](#) BC Decker Inc, Chap. 16

JA Henry et al. (2007) Tinnitus Retraining Therapy.

Clinical Guidelines, Chap. 11

Audiological measurements: Psychophysical measurements

- ▶ Pitch and ▶ loudness matching
- ▶ Minimum masking level (MML)
- ▶ Residual inhibition (RI)
- ▶ Loudness Discomfort Testing (LDL - Loudness growth)

Indication

- Standard tests used to characterise subjective description of tinnitus in all patients

Diagnostic value

- Useful in counseling (Pitch, loudness, Residual inhibition)
- Potentially useful in monitoring outcomes (MML)
- Useful in setting hearing aids (LDL)

Literature

JA Henry, MB Meikle (2000) Psychoacoustic measures of tinnitus.

J Am Acad Audiol. 2000 Mar;11(3):138-55.

R Tyler et al. (2008) American Journal of Audiology,

Snow JB (2004) Tinnitus – Theory and Management. BC Decker Inc, Chap. 16

JA Henry et al. (2007) Tinnitus Retraining Therapy.

Clinical Guidelines, Chap. 11

Pitch matching - Short description

One suggested method.

A two alternative forced choice method

- Two tones choose best match
- Example
 - 1 vs 2 kHz chooses 2 kHz
 - 2 vs 3 kHz chooses 3 kHz
 - 3 vs 4 kHz chooses 3 kHz
 - Check for “octave confusion” 3 vs 6 kHz
 - Should be undertaken at levels close to pitch match

For more details on “How to do” see Appendix B Henry JA & Zaugg TL (2005)
[Clinical Guide for Audiological Tinnitus Management I: Assessment.](#) AJA, 14, 21-48

Loudness matching - Short description

One suggested method.

At tinnitus pitch

- Determine auditory threshold
- Ascending increase in tone until subject reports external tone of equal loudness to tinnitus
- Most meaningful dB SL (sensation level) = dB HL(match) - dB HL(threshold)

For more details on “How to do” see Appendix B Henry JA & Zaugg TL (2005)
[Clinical Guide for Audiological Tinnitus Management I: Assessment.](#) AJA, 14, 21-48

Minimum masking level (MML) - Short description

One suggested method.

Minimum masking level

- NBN or BBN
- Record threshold to sound
- Record Lowest level which covers tinnitus
- Difference is MML

For more details on “How to do” see Appendix B Henry JA & Zaugg TL (2005)
[Clinical Guide for Audiological Tinnitus Management I: Assessment.](#) AJA, 14, 21-48

Residual Inhibition (RI) - Short description

One suggested method.

Residual inhibition

- MML + 10 dB
- Apply for 60 seconds
- “How does your tinnitus sound?”
- Record partial or full RI

For more details on “How to do” see Appendix B Henry JA & Zaugg TL (2005)
[Clinical Guide for Audiological Tinnitus Management I: Assessment.](#) AJA, 14, 21-48

Loudness Growth - Short description

One suggested method.

Contour Test (IHAFF)

- Uncomfortably loud (= LDL)
- Loud, but O.K.
- Comfortable, but slightly loud
- Comfortable
- Comfortable, but slightly soft
- Soft
- Very Soft

Rating of sounds preferably tones
For setting MPO of hearing aids
For describing loudness tolerance

RM Cox, GC Alexander, IM Taylor, GA Gray (1997) [The Contour Test of Loudness Perception](#). Ear and Hearing, 18(5):388-400



Audiological measurements: Tympanometry, stapedius reflex

Indication

Differential diagnosis of middle ear pathology

Short description

- Refer to Literature below for procedure.
- For better accuracy use manual driven instruments, always print the graphs. Stapedius reflex measure should be performed carefully to avoid worsening of tinnitus and after LDL if LDL doesn't indicate any major tolerance problem. Source of clear indications in case of clin. susp. of conductive hearing loss.

Diagnostic value

- Detection of surgical or medical curable tinnitus
- Middle ear problems detection,
- Otosclerosis detection,
- Olivecochlear bundle problems detection

Literature

Katz, Lippincott W & W (2009) Handbook of clinical audiology. Chap. 11, 12, 13

Audiological measurements: Tubal impedance-manometry

Indication

Tubal functionality test, very frequently this test can show air retaining in middle ear with moderate increase of transmission hearing loss and possible tinnitus increase.

Short description

Use tympanometric measure as evidence of eustachian tube function

Diagnostic value

for the diagnosis of middle ear dysfunction

Literature

Katz, Lippincott W & W (2009) Handbook of clinical audiology. Chap. 12

Audiological measurements:

DPOAE (following NP tinnitus constant + hearing loss - SN)

Short description (suggested method)

- High resolution DPOAE mode (8-10 pp/oct) is required in order to have a clear view of also minor OHC problem
- Tech. specs. high-definition DPOAE: L1/L2=65/55; f2/f1=1.22; f2 range: 1-8 kHz; 10 pp/octave

Diagnostic value

- Objective test of cochlear status,
- Assessment of outer hair cell function,
- Indication of suspected early stage hydrops (even if not proof with evidence),
- Important information for counselling (indication of cochlear damage as tinnitus trigger)

Literature

- Katz, Lippincott W & W (2009) Handbook of clinical audiology. Chap. 22
JA Henry et alt. (2007) Tinnitus Retraining Therapy. Clinical Guidelines, Chap. 11



Pulsatile tinnitus - arterial

Diagnostic criteria

- Heart beat synchronous pulsations
- Can disappear on manual compression of carotid artery in neck
- Can sometimes be perceived by auscultation

Differential diagnosis

- Atherosclerotic disease (carotid, subclavian)
- Dural arteriovenous fistulas
- Carotid-cavernous fistula
- Aneurysm (giant)
- Fibromuscular dysplasia of carotid artery
- Carotid artery dissection
- Aberrant internal carotid artery
- Hyperdynamic states (Anemia, thyrotoxicosis, pregnancy)
- Hypertension
- Internal auditory canal vascular loops
- Glomus jugulare tumor
- Benign intracranial hypertension

Literature

Mattox DE, Hudgins P. (2008) [Algorithm for evaluation of pulsatile tinnitus.](#)

Acta Otolaryngol. 2008 Apr;128(4):427-31

Sismanis A (1998) [Pulsatile tinnitus.](#) A 15-year experience. Am J Otol. 1998 Jul;19(4):472-7

Sismanis A (2003) [Pulsatile tinnitus.](#) Otolaryngol Clin North Am. Apr;36(2):389-402, viii. Review.

De Ridder et al. (2007) [An otoneurosurgical approach to non-pulsatile and pulsatile tinnitus.](#)

B-ENT. 2007;3 Suppl 7:79-86



Pulsatile tinnitus - venous

Diagnostic criteria

- Venous hum
- Can disappear on jugular vein compression (if possible with ultrasound control)

Differential diagnosis

- Benign intracranial hypertension (BIH)
- Sigmoid or jugular diverticulum
- High jugular bulb
- Transverse or sigmoid stenosis
- Condylar vein abnormalities

Literature

- Mattox DE, Hudgins P. (2008) [Algorithm for evaluation of pulsatile tinnitus](#). Acta Otolaryngol. 2008 Apr;128(4):427-31
- Sismanis A (1998) [Pulsatile tinnitus](#). A 15-year experience. Am J Otol. 1998 Jul;19(4):472-7
- Sismanis A (2003) [Pulsatile tinnitus](#). Otolaryngol Clin North Am. Apr;36(2):389-402, viii. Review.
- De Ridder et al. (2007) [An otoneurosurgical approach to non-pulsatile and pulsatile tinnitus](#). B-ENT. 2007;3 Suppl 7:79-86



Diagnostic criteria

Paroxysmally occurring tinnitus

Differential diagnosis

OBJECTIVE PAROXYSMAL TINNITUS:

- Palatal and middle-ear myoclonus,
- TMJ alterations (synchrony with joint movements)

SUBJECTIVE PAROXYSMAL TINNITUS:

- Cerebellopontine angle alterations (meningioma, arachnoid cyst, vascular compression...)
- Epilepsy
- Auditory hallucinations
- Migraine/aura (basilar)
- Phantom sensations without evidence of cortical or auditory system dysfunction.

Literature

Takano S et al. (1998) [Facial spasm and paroxysmal tinnitus associated with an arachnoid cyst of the cerebellopontine angle-case report](#). Neurol Med Chir (Tokyo) Feb;38(2):100-3

Espir J et al. (1997) [Paroxysmal tinnitus due to a meningioma in the cerebellopontine angle](#). Neurol Neurosurg Psychiatry. 1997 Apr;62(4):401-3

Brandt T, Dieterich M (1994) [VIIIth nerve vascular compression syndrome: vestibular paroxysmia](#). Baillieres Clin Neurol. Nov;3(3):565-75

Isu T et al. (1985) [Paroxysmal tinnitus and nystagmus accompanied by facial spasm](#). Surg Neurol. Feb;23(2):183-6



Tinnitus – constant + hearing loss - conductive

Diagnostic criteria

- Otoscopy
- Pure tone audiometry/Tuning fork testing
- Stapedius reflexes /Tympanometry
- Tubal manometry for a perforated or closed tympanum
- Star reflex
- CT Scan of the temporal Bone/X Ray of the Skull (Schüller)

Differential diagnosis

- Ear Wax
- Acute otitis media
- Otitis media with effusion
- Chronic otitis media
- Cholesteatoma
- Otosclerosis
- Ossicular chain trauma
- Ossicular malformations
- External or middle ear cancer

Literature

Gristwood RE, Venables WN (2003) [Otosclerosis and chronic tinnitus.](#)
Ann Otol Rhinol Laryngol. May;112(5):398-403

Minor LB (2005) [Clinical manifestations of superior semicircular canal dehiscence.](#)
Laryngoscope. Oct;115(10):1717-27



Tinnitus – constant + hearing loss – sensory neural

Diagnostic criteria:

- Audiometry: SNHL
- Metz Test (stapedial reflex): positive if recruitment
- Otoacoustic emissions. Distortion products
- Auditory Brainstem Responses
- MRI Posterior Fossa (with gadolinium contrast)
- Blood test for metabolic and immunology:
 - Hemogram, Zinc
 - FTA for oto-siphilis
 - Glucose. If Meniere's disease: 5h-curve on glucose and insulin
 - If Autoimmune Inner Ear Disease: GSV, Immunoglobulines, Complement factors, ANA, Rheumatoid Factor, Immunophenotype, Western blot for heat shock protein-70

- Genetic tests
- Stapedius(reflex and thresholds) / Tympanometry/Reflex Decay test
- Fistula searching
- CT Scan of the temporal Bone
- MRI and/or BAEP – if unilateral or asymmetric hypoacusia

Differential diagnosis:

- Labyrinth malformations
- Viral pediatric infections: mumps, measles, rubella, etc.
- Genetic hearing loss: syndromic, non-syndromic
- Immune-mediated inner ear disease
- Cochlear otosclerosis
- Cochlear endolymphatic hydrops
- Cochlear ototoxicity
- Ménière's disease
- VIII cranial nerve tumor
- Metabolical disorders
- Noise induced hearing loss
- Acoustic trauma
- Otologic / temporal bone trauma
- Sudden deafness
- Barotrauma
- Labyrinthitis (bacterial, viral, tuberculosis, fungical)
- Idiopathic hearing loss
- Auditory neuropathy / dis-synchrony
- Central auditory processing disorders

Literature

- Snow JB (2004) [Tinnitus – Theory and Management](#) (chap.15 and 16)
- Baloh RW (1999) [Dizziness, hearing loss and tinnitus](#). Arch neurol-vol.56 No 12, December, Philadelphia,Pa,FA Davis Co

Tinnitus – constant + vertigo

Diagnostic criteria

- Tonal audiometry (bone and air conduction)
- Tympanometry (Stapedius reflexes and thresholds)
- Decay reflex test
- Fistula searching
- MRI and/or BAEP - if hypoacusia and/or tinnitus are unilateral and/or asymmetric
- Clinical Vestibular Examination: nystagmus, axial and segmentary deviation's searching, Fukuda-test, study of the cranial nerves
- if needed: instrumental Vestibular Examination: e.g. oculomotricity, spontaneous and provoked nystagmus, Head shaking test, Kinetic and Caloric tests, Subjective vertical test, high frequency vibratory stimulation, Positional vertigo and nystagmus searching

Differential diagnosis

- Ménière's disease
- VIII cranial nerve tumor-Cholesteatoma
- Labyrinthitis (viral, bacterial..)
- Cochlear otosclerosis-central auditory and/or vestibular disorders

Literature

- Ulmer E (1993) Actualités sur les vertiges du point de vue de l'O.R.L. = Recent advances in vertiges. [Les Cahiers d'oto-rhino-laryngologie, de chirurgie cervico-faciale et d'audiophonologie](#). vol. 28, no1, pp. 9-15
- Said J, Izita A. (2006) [Study of test of balance in tinnitus and vertigo patients](#). Int Tinnitus J.;12(1):57-9



Tinnitus – constant + headache

Diagnostic criteria / differential diagnosis

- Bilateral (more frequently)/unilateral tinnitus accompanying constant headache as a somatosensory symptom of tension-type headache. (Typically constant dull, moderate headache without nausea, vomiting, photo / sonophobia; frequently tinnitus lateralisation corresponds to headache lateralization)
- Tinnitus and constant headache in benign intracranial hypertension
- The headache is usually holocraneal, dull and constant, increase with the Valsalva maneuver and is associated with papilledema in the neurological examination

Literature

- Wall M (2008) [Idiopathic intracranial hypertension \(pseudotumor cerebri\)](#).
Curr Neurol Neurosci Rep. Mar;8(2):87-93
- Fierro M et al. (2006) [[Repeated transcranial magnetic stimulation in a patient with chronic bilateral tinnitus](#)][Article in Spanish] Rev Neurol. Dec 16-31;43(12):758-9



Tinnitus – constant + psychiatric

Diagnostic criteria

- Suspicion of psychiatric comorbidity:
- Symptoms of depression, anxiety, OCD, somatoform disorders, posttraumatic stress disorder, psychosis or dementia in the first consultation
- Suspicion of psychiatric comorbidity especially with high scores in tinnitus questionnaires (grade III or IV according to Biesinger; TQ > 47; THI > 37),
- In case of suspicion of psychiatric disorder further diagnostic evaluation by a specialist (psychiatrist, clinical psychologist)

Differential diagnosis

depression, anxiety, somatoform disorders, OCD, posttraumatic stress disorder, psychosis or dementia

Literature

Langguth et al. (2007) Prog Brain Res.;166:221-5

Zoger et al. (2006) [Relationship between tinnitus severity and psychiatric disorders](#). Psychosomatics;47(4):282-8

Unterrainer et al. (2003) [Experiencing tinnitus: which factors are important for perceived severity of the symptom?](#) Int Tin J;9(2):130-3



Tinnitus – constant + somatosensory – neck Constant tinnitus and modulation induced by neck movements

Diagnostic criteria

On physical exam (tests should be performed in a silent environment):

A. Immediate tinnitus changes during active neck movements (with or without resistance):

- forward / backward
- rotation
- lateralization

B. Immediate tinnitus changes during passive muscular palpation:

- sternocleidomastoid
- trapezius
- suboccipital

Observations:

- the modulation can occur with or without concomitant pain
- both increases and decreases in loudness reinforce the somatosensory involvement, but the decreases seem to have better prognostic to cure/improve tinnitus after muscular manipulation

Literature

- Sanchez TG et al. (2002) [The influence of voluntary muscle contractions upon the onset and modulation of tinnitus](#). *Audiol Neurootol*.;7:370-5
- Abel MD, Levine RA (2004) [Muscle contractions and auditory perception in tinnitus patients and nonclinical subjects](#). *Cranio*.;22(3):181-91
- Levine RA (1999) [Somatic \(craniocervical\) tinnitus and the dorsal cochlear nucleus hypothesis](#). *Am J Otolaryngol*.;20:351-62
- Levine RA (2001) *Assoc Res Otolaryngol*.;24:15
- Sanchez TG et al. (2007) [Somatic modulation of tinnitus: test reliability and results after repetitive muscle contraction training](#). *Ann Otol Rhinol Laryngol*.;116(1):30-5



Tinnitus – constant + somatosensory – TMJ

Constant tinnitus and modulation induced by temporomandibular joint movements

Diagnostic criteria

On physical exam (tests should be performed in a silent environment):

A. Immediate tinnitus changes during active jaw movements (with or without resistance):

- Opening / closing
- Forward / backward
- Lateralization

B. Immediate tinnitus changes during passive muscular palpation:

- Masseter
- Temporalis
- Pterygoid (controversial)
- Immediate tinnitus changes during the fatigue test (close teeth with spatula between them in anterior, left and right positions for one minute)

Observations:

The modulation can occur with or without concomitant pain

Literature

- Rubinstein B (1990) [Prevalence of signs and symptoms of craniomandibular disorders in tinnitus patients.](#) J Craniomandib Disord.;4(3):186-92;
- Sanchez TG et al. (2002) [The influence of voluntary muscle contractions upon the onset and modulation of tinnitus.](#) *Audiol Neurootol.*;7:370-5;
- Levine RA. (2001) *Assoc Res Otolaryngol.*;24:15;
- Abel MD (2004) [Muscle contractions and auditory perception in tinnitus patients and nonclinical subjects.](#) Cranio.;22(3):181-91
- Björne A (2007) [Assessment of temporomandibular and cervical spine disorders in tinnitus patients.](#) Prog Brain Res.;166:215-9;
- Sanchez TG et al. (2007) [Somatic modulation of tinnitus: test reliability and results after repetitive muscle contraction training.](#) Ann Otol Rhinol Laryngol. Jan;116(1):30-5



Hyperacusis

Diagnostic criteria

- Decreased sound tolerance test (GÜF, Nelting 03)
- Loudness Discomfort Levels
- Efferent system test with Otoacoustic Emissions
- Auditory Brainstem Responses
- MRI Posterior Fossa

Differential diagnosis

- Peripheral disorders:
 - Cochleopathy:- Hyperactivity of external ciliary cells (?)
 - Ménière's disease. Endolymphatic hydrops
 - Perylymphatic istula
 - Sudden deafness
 - Acoustic trauma
 - Otosclerosis
 - After surgery:- After stapedotomy / stapedectomy
 - After tympanic tube placement
 - After wax extraction
 - Stapedial reflex disorder: - Ramsay-Hunt Sdr.
 - Facial nerve paralysis
 - Muscular Disorders: - Miastenia gravis
- Central disorders:
 - Migraine
 - Depression. Posttraumatic stress sdr.
 - Cranio-encephalic trauma
 - Lyme disease
 - Williams sdr.
 - Benzodiazepine abscence sdr.
 - Chronic fatigue sdr.
 - Tay-Sachs sdr (gangliosidosis 2)
 - Multiple sclerosis
 - Benign intracranial hypertension sdr.

Literature

- Nelting M, Rienhoff NK, Hesse G, Lamparter U (2002) [\[The assessment of subjective distress related to hyperacusis with a self-rating questionnaire on hypersensitivity to sound.\]](#) [Article in German]Laryngorhinootologie; 81: 32-4
- Jastreboff PJ + MM (2003) [Tinnitus retraining therapy for patients with tinnitus and decreased sound tolerance.](#) Otolaryngol Clin North Am. Apr;36(2):321-36. Review



Post traumatic tinnitus

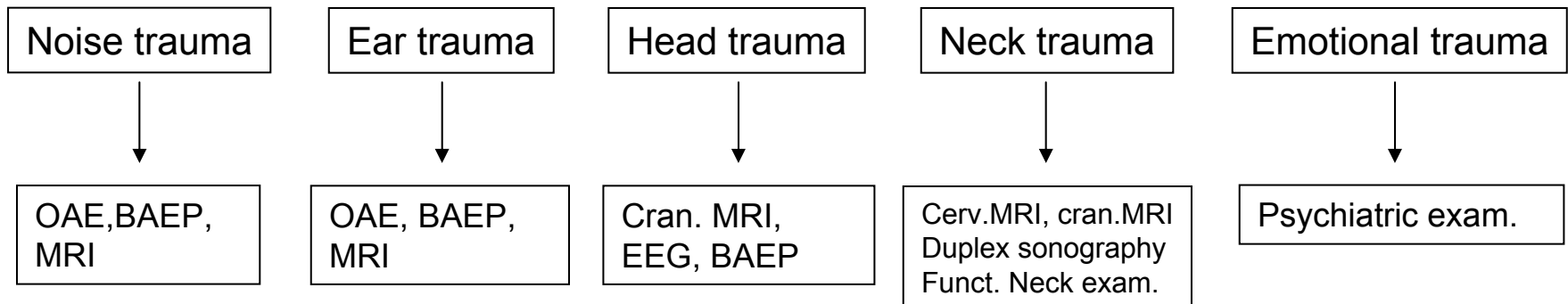
Diagnostic criteria

tinnitus starting or worsening after noise-, ear-, head-, neck- or emotional trauma
A potential relationship between tinnitus and a traumatic event should be considered, if tinnitus begins or worsens within 3 months after the trauma event. In case of pulsatile tinnitus, immediate diagnostic workup for vascular pathologies (especially carotide dissection) necessary.

Differential diagnosis

tinnitus starting incidentally after traumatic event, not causally related with the trauma

Further diagnostic steps



NOTE: In case that Post traumatic Tinnitus manifest as pulsatile tinnitus, follow the diagnostic path detailed on [▶ slide 2](#).

Post traumatic tinnitus

Non-pulsatile tinnitus

- Otological
 - Temporal bone fracture: in 50 % tinnitus develops (Chen 2001)
 - Labyrinthine concussion: tinnitus common (Baloh 1998)
 - Ossicular chain disruption: associated with fracture in 15% (Wennmo 1993)
 - Perilymphatic fistula: in 61-76% tinnitus develops (Glasscock 1992)
 - Barotrauma: in 66-88% of blast injuries tinnitus develops (Mrena 2004, Persaud 2003)
 - Noise trauma: induces high pitched whistling tinnitus (Nicolas-Puel 2006)
- Psychological
 - PTSD: in 50% tinnitus is present (Hinton 2006)
- Cervical
 - Neck trauma associated

Pulsatile tinnitus

- Carotid dissection: in 16-27% pulsatile tinnitus (Redekop 2008, Baumgartner 2005)
- AV fistula: can develop after days, weeks or years (D'Alise 1997, Freckman 1981)
- Caroticocavernous fistula: most common, in 3.8% of skull base fractures, in 8.3% of middle fossa fractures (Liang 2007)

Literature

- Claussen CF (1995) [Neurootological contributions to the diagnostic follow-up after whiplash injuries](#). Acta Otolaryngol Suppl.;520 Pt 1:53-6
- Fagelson MA (2007) [The association between tinnitus and posttraumatic stress disorder](#). Am J Audiol. Dec;16(2):107-17



Cardiovascular examination

Indication

- Suspicion of a cardio-vascular origin and/or modulation of the tinnitus modulation or disappearance of the tinnitus on some body, head or neck positions. In these cases the tinnitus can be induced or modulated by a neck hemodynamic problem in static or dynamic conditions
- Carotid or vertebral dissection such as unilateral neck pain or headache, face numbness, Horner's syndrome, transitory ischemic attacks etc.

Short description

- Blood pressure (evtl. lying and upright), cardiac and neck auscultation, electrocardiography, echocardiography
- Echo-Doppler of neck vessels. Measurement of flows, resistances and thickness of the Intima. Search of an arterial-venous fistula, atheroma plates, stenoses and vascular loops, dissection vessels

Diagnostic value

Tinnitus related to arterial hypertension or hypotension, cardiac rhythm abnormalities, ischemia, heart décompensation hemodynamic and vascularization
Proof or exclusion of neck vessel disorders
pathologies of neck vessels such as Arterial-venous fistula, arterial stenoses, vascular loops, and dissection vessels can manifest as tinnitus

Evidence level / Literature

Diagnostic clues in pulsatile tinnitus (somatosounds)

Herraiz C, Aparicio JM (2007) [\[Diagnostic clues in pulsatile tinnitus \(somatosounds\)\]](#) [Article in Spanish]. Acta Otorrinolaringol Esp. Nov;58(9):426-33. Links

Tinnitus caused by traumatic posterior auricular artery--internal jugular vein fistula.

Chae SW, Kang HJ, Lee HM, Hwang SJ (2001) [Tinnitus caused by traumatic posterior auricular artery--internal jugular vein fistula.](#) J Laryngol Otol. Apr;115(4):313-5. Links



Angiography

Indication

- Pulsatile tinnitus evaluation with/without occlusion testing and embolization
- Very careful indication, If possible less invasive techniques

Short description

- Insertion via Seldinger technique of contrast in arterial or venous circulation
- Dilate a balloon and verify if tinnitus improves
- Embolize vascular anomalies

Diagnostic value

- Retrieve arterial and venous vascular anomalies
- Perform occlusion tests
- Embolize

Remark: 0,1% risk of permanent neurological deficit

Literature

Sila CA (1987) [Pulsatile tinnitus](#). Stroke. Jan-Feb;18(1):252-6

Shin EJ et al. (2000) [Role of angiography in the evaluation of patients with pulsatile tinnitus](#). Laryngoscope. Nov;110(11):1916-20.

Mattox DE, Hudgins P (2008) [Algorithm for evaluation of pulsatile tinnitus](#). Acta Otolaryngol. Apr;128(4):427-31



Angio - MRI

Indication

Pulsatile tinnitus evaluation, preferable compared to Angiography

Short description

- MRI with or without gadolinium contrast
- Without contrast
 - Flow based MRA : TOF (time of flight) or phase-contrast MRA
 - True FISP and bTFE (based on different signal properties of blood)
- Contrast based : gadolinium

Diagnostic value

- Retrieve arterial and venous vascular anomalies

Literature

Dietz RR et al (1994) [MR imaging and MR angiography in the evaluation of pulsatile tinnitus.](#) AJNR Am J Neuroradiol. May;15(5):879-89

EEG (following tinnitus paroxysmal)

Indication

- Paroxysmal bilateral/unilateral tinnitus (especially with further signs of seizures)
- especially indicated in Paroxysmal tinnitus with consciousness disturbance, progressive pitch or complex sounds and with variable periods between episodes

Short description

Standard EEG, eventually with provocation (flashlight, hyperventilation)

Diagnostic value

- epileptic focus in temporal or temporal with secondary generalization
- Video-EEG demonstrative if tinnitus coexists with temporal lobe discharges

Literature

Eggermont JJ (2007) [Correlated neural activity as the driving force for functional changes in auditory cortex](#). Hear Res. Jul;229(1-2):69-80

Cendes F et al (2005) [Familial temporal lobe epilepsy with auditory features](#). Epilepsia, 46, suppl 10

Gordon AG (2003) [Temporal lobe epilepsy and auditory symptoms](#). JAMA. Nov 12;290(18):2407; author reply 2407



MRI (following tinnitus paroxysmal)

Indication

Any paroxysmal tinnitus without any evidence of extracranial/intracranial disorder proved

Short description

MRI shows cerebellopontine angle disorders, cortical ectopias, TMJ disorders,

Diagnostic value

- Cerebellopontine angle disorders (arachnoid cyst, vascular malformations, Brain tumours, Arnold-Chiari)
- Microvascular compression
- Cortical ectopias
- TMJ disorders
- indirect signs of benign intracranial hypertension
- indirect signs of liquoral hypotension

Literature

- Couch JR (2008) [Spontaneous intracranial hypotension: the syndrome and its complications](#). Curr Treat Options Neurol. Jan;10(1):3-11
- Pruszewicz A et al (2007) [[Tinnitus as the first symptom of Arnold-Chiari-Syndrome](#)][Article in Polish]. Otolaryngol Pol.;61(6):998-9
- Safdar A et al (2008) [Aberrant ectatic internal carotid artery in the middle ear](#). Ear Nose Throat J. Apr;87(4):214-6
- Sugiura S et al (2008) [Tinnitus and brain MRI findings in Japanese elderly](#). Acta Otolaryngol. May;128(5):525-9



BAEP (following tinnitus paroxysmal)

Indication

- in paroxysmal tinnitus indicated for screening of nerve compression only, if MRI not available or not possible (e.g. patient with pacemaker)
- **Functional and structural assessment of the auditory pathways up to the inf. colliculus**
- In case of microvascular compression indicated as prognostic marker

Short description

- Peak I-II correlates with tinnitus
- IPL I-III with hearing loss at tinnitus frequency
- IPL III-Vc with compensation (unpublished data)

Diagnostic value

- Only valuable for MVC as more compressions are seen on MRI than symptomatic
- Patients should be surgically decompressed before IPL I-III prolongs

Literature

- Møller MB, Møller AR et al (1993) [Vascular decompression surgery for severe tinnitus: selection criteria and results](#). Laryngoscope. Apr;103(4 Pt 1):421-7.
- De Ridder D (2007)
- Ryu et al (1998) [Neurovascular decompression of the eighth cranial nerve in patients with hemifacial spasm and incidental tinnitus: an alternative way to study tinnitus](#). Neurosurg. Feb;88(2):232-6



MRI (following tinnitus constant + hearing loss - SN)

Indication

Exclude possible treatable causes of tinnitus, especially in unilateral hearing loss:

Short description

- T1,T2, CISS, Flair, etc
- With and without contrast

Diagnostic value

- Microvasc. compression (MVC)
- Canal dehiscence
- N VIII tumor
- Chiari
- Space occupying lesions (SOL)
- Cerebrovascular accident (CVA)

Literature

Branstetter (2006) [The radiologic evaluation of tinnitus](#). Eur Radiol. Dec;16(12):2792-802.

Kang M, Escott E (2008) [Imaging of tinnitus](#). Otolaryngol Clin North Am. Feb;41(1):179-93, vii

Sugiura S (2008) [Tinnitus and brain MRI findings in Japanese elderly](#). Acta Otolaryngol. May;128(5):525-9



BAEP (following tinnitus constant + hearing loss - SN)

Indication

Screening tool for acoustic nerve pathology, in case that MRI is not available **see ► [slide 36](#)**

Short description

- BAEP at high intensities while identifying the first 5 waves of the Brain Stem, the variations of inter-waves and inter-auricular conduction, appreciation of the correlation between the objective thresholds to the CLICK and the data of the tonal audiogram.

Diagnostic value

If pathologic, MRI has to be performed)

Literature

Mahillon V et al (2003) [[Diagnostic management of unilateral sensorineural hearing loss in adults](#)][Article in French] Rev Med Brux. Feb;24(1):15-9



MRI (following tinnitus constant + vertigo)

Indication

Uni- or bilateral symmetric or asymmetric tinnitus associated with a an unbalance or a vertigo.

Short description

MRI on the whole of brain

A location in the sagittal plan in T1: petro-occipital joint

A diffusion sequence : Recent AVC

FLAIR and CISS sequence

following sequences are centered on the posterior fossa

T2 volume: neuroma

T1 Volume with injection: neuroma, arterial or venous vascular anomalies

Angiography (ARM): arteries.

Diagnostic value

Neuroma, arterial or venous vascular anomalies, petro-occipital joint anomalies, recent Stroke, MVC

Literature

Schick B et al (2001) [Magnetic resonance imaging in patients with sudden hearing loss, tinnitus and vertigo.](#) Otol Neurotol; 22:808–812

BAEP (following tinnitus constant + vertigo)

Indication

for screening of auditory nerve pathology in uni- or bilateral symmetric or asymmetric tinnitus associated with an imbalance or a vertigo, only if MRI is not available **see**

▶ slide 36.

Short description

BAEP at high intensities while identifying the first 5 waves of the Brain Stem, the variations of inter waves and inter auricular conduction, appreciation of the good correlation between the objective thresholds to the CLICK and the data of the tonal audiogram. Sometimes it is interesting to modify the recurrence or the polarity of the CLICK for a better extraction of the wave I. Ratio of the I and V waves amplitudes, appreciation of some labiality of the wave V and dysmorphism of the complex IV-V (Multiple sclerosis).

Diagnostic value:

If BAEP is pathologic, MRI has to be performed (Acoustic neuroma, dissociated Ménière, multiple sclerosis, Brain stem tumoral or vascular pathologies...)

Literature

Rambold H (2005) [Differential vestibular dysfunction in sudden unilateral hearing loss.](#) Neurology. Jan 11;64(1):148-51



ECoG (following tinnitus constant + vertigo)

Indication

ECoG is a sensitive measure for endolymphatic hydrops and can be indicated in doubtful cases of unilateral tinnitus and vertigo, to differentiate endo- or retrocochlear origin.

Short description

installation of a transtympanic electrode on the headland to assess a cochlear potential that can compare to the wave 1 of the BAEP while CLICKS stimulation. The ECoG potential has 3 main components, the Cochlear Microphonism (CM), summation potential (SP) and Compound Action Potential (CAP) 9 . It can be registered with transtympanic, tympanic or extratympanic electrodes thus representing a more or less invasive procedure

Diagnostic value

sensitive indicator for endolymphatic hydrops

Literature

Aran, J-M (1968) Assistent of non-invasive electrocochleography

Rotter A et al. (2008) [Low-frequency distortion product otoacoustic emission test compared to ECoG in diagnosing endolymphatic hydrops.](#) Eur Arch Otorhinolaryngol. Jun;265(6):643-9

Ferraro JA, Durrant JD (2006) [Electrocochleography in the evaluation of patients with Ménière's disease/endolymphatic hydrops.](#) J Am Acad Audiol.17(1):45-68. Level II-3



MRI (following tinnitus constant + headache)

Indication

- Tinnitus + Headache
- Worsening during Valsalva, bending over or reclining (positional)

Short description

Often associated with pulsatile component

Diagnostic value

- Space occupying lesion (tumor, arachnoid cyst, abscess...)
- Chiari Malformation
- Benign Intracranial Hypertension
- Spontaneous intracranial hypotension

Literature

....

Furosemide test (following tinnitus constant + headache)

Indication

Suspicion of benign intracranial hypertension (BIH)

Short description

- Furosemide per os or IV (40 to 80 mg morning) for 3-10 days
(Cave: control of electrolytes)
- Tinnitus reduction after furosemide application

Diagnostic value

- Positive test could potentially indicate raised pressure

Literature

LP (following tinnitus constant + headache)

Indication

Patients with suspected BIH responding to furosemide

Short description

- Perform LP in lateral decubitus
- Measure opening pressure
- Evacuate 40 cc

Diagnostic value

If tinnitus improves on LP, ventriculoperitoneal shunt can be considered

Literature

Psych Exam (following tinnitus constant + psychiatric)

Indication

- Severe tinnitus often accompanied by psychiatric comorbidity (e.g. depression, anxiety disorder, insomnia, somatoforme disorder)¹
- Psychiatric consultation indicated in case of decompensated tinnitus (grade III or IV according to Biesinger; TQ > 47, THI > 37), history of psychiatric disease or suspicion of psychiatric disease based on the first consultation.
- A helpful guide for screening can be found here:
www.aafp.org/afp/981101ap/carlat.html

Immediate referral to a psychiatrist in case of suicidality

Short description

- Psychiatric interview
- Psychometric evaluation if necessary

Diagnostic value

Diagnosis of comorbid psychiatric diseases (depression, anxiety disorder, insomnia, somatoforme disorder)

Literature

- Hiller W, Goebel G (2002) [A psychometric study of complaints in chronic tinnitus. Journal of Psychosomatic Research.](#) 36 (4), 337-348
- Zöger et al (2006) [Relationship between tinnitus severity and psychiatric disorders.](#) Psychosomatics. Jul-Aug;47(4):282-8



Screening form psychiatric comorbidity - One suggested method.

Screening questions for depressive episodes:

- during the past month have you often been bothered by feeling down, depressed, or hopeless?
- during the past month have you often been bothered by little interest or pleasure in doing things?

If „yes“ to one of these questions, further diagnosis by psychiatrist is indicated

Literature: Whooley et al (2000) [Managing depression in medical outpatients](#). *N Engl J Med*.343:1942-1950

Screening questions for anxiety disorders:

1. Have you, on more than one occasion, had spells or attacks when you suddenly felt anxious, frightened, uncomfortable or uneasy, even in situations where most people would not feel that way ? Did the spells surge to a peak, within 10 minutes of starting ? Code YES only if the spells peak within 10 minutes.
2. Do you feel anxious or uneasy in places or situations where you might have a panic attack or panic-like symptoms, or where help might not be available or escape might be difficult : like being in a crowd, standing in a line (queue), when you are away from home or alone at home, or when crossing a bridge, traveling in a bus, train or car ?
3. In the past month were you fearful or embarrassed being watched, being the focus of attention, or fearful of being humiliated ? This includes things like speaking in public, eating in public or with others, writing while someone watches, or being in social situations.
4. In the past month have you been bothered by recurrent thoughts, impulses, or images that were unwanted, distasteful, inappropriate, intrusive, or distressing ? (e.g., the idea that you were dirty, contaminated or had germs, or fear of contaminating others, or fear of harming someone even though you didn't want to, or fearing you would act on some impulse, or fear or superstitions that you would be responsible for things going wrong, or obsessions with sexual thoughts, images or impulses, or hoarding, collecting, or religious obsessions.)

Interpretation:

If “Yes” to 1.: suspicion of panic disorder

If “Yes” to 2.: suspicion of agoraphobia

If “Yes” to 3.: suspicion of social phobia

If “Yes” to 4.: suspicion of specific phobia

Literature:

Sheehan DV et al (1997) [Reliability and Validity of the MINI International Neuropsychiatric Interview \(M.I.N.I.\): According to the SCID-P](#). *European Psychiatry*. 12:232-241



TMJ (following tinnitus constant + somatosensory)

Indication

tinnitus modulation during movements involving the TMJ and/or tinnitus in the presence of classical signs and symptoms of TMD (pain in the chewing muscles and/or jaw joint, limited movement or locking of the jaw, radiating pain in the face, neck or shoulders, painful clicking, popping or grating sounds in the jaw joint when opening or closing the mouth, headache, earache, dizziness, aural fullness)

Short description

- MRI, CT scan or X ray, being the first the more detailed exam.
- However, anamnesis plus clinical examination might be enough in many cases.

Diagnostic value

Bony problems of TMJ may justify the presence of the pain and the maintenance of muscular problems (although they may occur isolated) and are seldom reversed with treatment, unless they have surgical indication.

Literature

Montagnani G (2005) [Magnetic resonance of the temporomandibular joint: experience at an Italian university center.](#) Minerva Stomatol. Jul-Aug;54(7-8):429-40



Neck Imaging (following tinnitus constant + somatosensory)

Indication

Tinnitus modulation during movements involving the neck and/or tinnitus in the presence of pain in the neck

Short description

- MRI, CT or X-Ray with flexion & extension of the neck
- Bone scintigraphy

Diagnostic value

- rectification of the natural curvature indicates muscular tension
- most bony diseases (osteophytes, arthrosis, spondylosis, etc) may justify the pain and the maintenance of muscular problems (although they may occur isolated)

CAVE: imaging is essential before manual manipulation

Literature

- Morishita Y, Naito M, Hymanson H, Miyazaki M, Wu G, Wang JC (2009) [The relationship between the cervical spinal canal diameter and the pathological changes in the cervical spine.](#) Eur Spine J. Apr 9
- Theocharopoulos N, Chatzakis G, Karantanas A, Chlapoutakis K, Damilakis J (2009) [CT evaluation of the low severity cervical spine trauma: When is the scout view enough?](#) 1: Eur J Radiol. Apr 15
- Baumert B, Wörtler K, Steffinger D, Schmidt GP, Reiser MF, Baur-Melnyk A (2009) [Assessment of the internal craniocervical ligaments with a new magnetic resonance imaging sequence.](#) Magn Reson Imaging. Mar 17
- Ribbons T, Bell S (2008) [Neck pain and minor trauma: normal radiographs do not always exclude serious pathology.](#) Emerg Med J. Sep;25(9):609-10
- Nidecker A, Pernus B, Hayek J, Ettlin T (1997) [\["Whiplash" injury of the cervical spine: value of modern diagnostic imaging.\]](#) Schweiz Med Wochenschr. Oct 4;127(40):1643-51



Suicidality

Diagnostic criteria

- Risk of Suicidality may be increased in chronic tinnitus patients, especially with comorbid depressive disorder.
- Warning signs may be severe depressed mood, which can not be modulated; social withdrawal; suicide thoughts or suicidal behaviour
- Severeness of suicidality should be explored by asking the patient about potential thoughts of committing suicide or if he/she is having concrete plans
- Cave: Mentioning potential suicidality does not increase the risk of committing suicide

Treatment recommendation

- In case of suicidality: immediate referral to a psychiatrist, in-patient treatment, benzodiazepines (Level III)

Literature:

Lewis JE et al (1994) [Tinnitus and suicide](#). Clin Otolaryngol Allied Sci. Feb;19(1):50-4

Jacobson GP and McCaslin DL (2001) [A search for evidence of a direct relationship between tinnitus and suicide](#). J Am Acad Audiol. Nov-Dec;12(10):493-6

Turner et al (2007) [Suicide in deaf populations: a literature review](#). Ann Gen Psychiatry. Oct 8;6:26

[Guidelines for Identification, Assessment and Treatment planing of Suicidality](#),
(<http://www.rm.f.harvard.edu/files/documents/suicideAs.pdf>)

Suicidality

In case of suspected suicidality, careful exploration is necessary, The most effective approach for assessing suicidal ideation is to ask first about passive suicidal ideation. This sensitive area may be introduced with the question, "In the past month did you think that you would be better off dead or wish you were dead ? "

Screening questions:

C. SUICIDALITY

In the past month did you:

C1	Think you would be better off dead or wish you were dead?	<input type="radio"/> No	<input type="radio"/> Yes	1
C2	Want to harm yourself?	<input type="radio"/> No	<input type="radio"/> Yes	2
C3	Think about suicide?	<input type="radio"/> No	<input type="radio"/> Yes	6
C4	Have a suicide plan?	<input type="radio"/> No	<input type="radio"/> Yes	10
C5	Attempt suicide?	<input type="radio"/> No	<input type="radio"/> Yes	10
C6	In your lifetime: Did you ever make a suicide attempt?	<input type="radio"/> No	<input type="radio"/> Yes	4

IS AT LEAST 1 OF THE ABOVE CODED YES?

IF YES, ADD THE TOTAL NUMBER OF POINTS FOR THE ANSWERS (C1-C6) CHECKED 'YES' AND SPECIFY THE LEVEL OF SUICIDE RISK AS FOLLOWS:

<input type="radio"/> No	<input type="radio"/> Yes
SUICIDE RISK CURRENT	
1-5 points Low	<input type="radio"/>
6-9 points Moderate	<input type="radio"/>
>=10 points High	<input type="radio"/>

Literature:

Sheehan DV et al (1997) [Reliability and Validity of the MINI International Neuropsychiatric Interview \(M.I.N.I.\): According to the SCID-P.](#) European Psychiatry. 12:232-241



Arteriovenous malformation

Diagnostic criteria

Arterial pulsatile tinnitus

Short description

- Dilated arteries and veins with dysplastic vessels
- Bleeding risk of 2-4% per year
- Demonstrated by MRI, MRA, Angiography

Treatment recommendation

- Embolization in multiple stages
- Surgical resection if intractable to embolization

Literature

Sinus thrombosis

Diagnostic criteria

- Bilateral/unilateral tinnitus of acute/subacute onset with signs/symptoms of Sinus venous thrombosis: headache, papilledema, seizures
- MRI with venous MRI angiography, venous CT angiography
- further diagnosis for detecting the etiology (Blood test etc.)

Treatment recommendation

- Acute treatment with intravenous heparine for 10-14 days (aiming at a PTT of 60-80 s) (I)
- alternatively low molecular heparine (IIA)
- oral anticoagulation for 3-6 months (INR 2-3)(I)
- surgical treatment and antibiotic treatment in case of local infection (I)
- osmotherapeutic treatment in case of increased intracranial pressure (IIB)
- antiepileptic drugs if needed

Literature

Sigari F et al (2006) [Headache with unilateral pulsatile tinnitus in women can signal dural sinus thrombosis](#). Ann Otol Rhinol Laryngol. Sep;115(9):686-9.

Schütt F et al (1998) [[Periorbital pressure and papilledema.Papilledema, episcleral glaucoma and tinnitus in multiple dura fistulas and sinus thrombosis](#)][Article in German] Ophthalmologe. Dec;95(12):844-5

Kearon et al (2003)



Aneurysm

Diagnostic criteria

- Tinnitus with or without history of sudden severe headache
- Aneurysm very rare in pulsatile tinnitus (1/84 pulsatile tinnitus patients)
- esp. petrous ICA aneurysms present with tinnitus

Treatment recommendation

Clipping, coiling, wrapping, trapping or observation, depending on size, localisation, history of bleeding of other aneurysms, patient age (IIB)

Literature

Wiebers DO et al (2003) [Unruptured intracranial aneurysms: natural history, clinical outcome, and risks of surgical and endovascular treatment](#) (ISUIA - The International Study of Unruptured Intracranial Aneurysms Investigators). Lancet;362:103-110.



Glomus Tumor

Diagnostic criteria

- = paraganglioma = chemodectoma
- Women (6:1) with hearing loss and pulsatile tinnitus
- Four different kinds (carotid body, glomus jugulare, glomus tympanicum, glomus intravagale)
- Unilateral
- Benign (<10 % with lymph node involvement or distant spread)
- Grow <2 cm / 5 year
- Otoscopy
- MRI-angio + CT scan

Treatment recommendation

- Surgical removal
- follow or embolize
- irradiation

Literature

- Boedeker CC et al (2005) [Paragangliomas of the head and neck: diagnosis and treatment](#). Fam Cancer. 4(1):55-9.
- Varma A et al (2006) [Gamma knife radiosurgery for glomus jugulare tumors: volumetric analysis in 17 patients](#). Neurosurgery. Nov;59(5):1030-6; discussion 1036
- Blackburn W et al (2007) [Brain Tumour Foundation Award 2007. Glomus jugulare tumours: are they really so benign?](#) Can J Neurosci Nurs. 29(2):21-8



Carotid Stenosis

Diagnostic criteria

Tinnitus related with significant ipsilateral or contralateral carotid stenosis
Causal relationship is difficult to judge; treatment recommendations are independent from a possible causal relationship

Diagnostic procedures

Carotid eco-duplex, MRI with vascular MRI, angiography

Treatment recommendation

- Symptomatic carotid stenosis more than 70%: carotid angioplasty (contralateral Concomitant stenosis, age >65 years, vascular risk factors, etc) or endarterectomy
- clopidogrel, statins and antihypertensive drugs (without tinnitus as an adverse Effect) (I)
- Tinnitus could persist after treatment

Literature

- De Ridder D et al (2007) [An otoneurosurgical approach to non-pulsatile and pulsatile tinnitus.](#) B-ENT. 3 Suppl 7:79-86
- Hafeez F et al (1999) [Pulsatile tinnitus in cerebrovascular arterial diseases.](#) J Stroke Cerebrovasc Dis. July - August;8(4):217-223
- Merigeaud S et al (2005) [\[Tinnitus and stenosis of the cavernous internal carotid artery\]\[Article in French\]](#) J Neuroradiol. Sep;32(4):273-7
- Halliday A, Mansfield A, Marro J, Peto C, Peto R, Potter J, et al (2004) [Prevention of disabling and fatal strokes by successful carotid endarterectomy in patients without recent neurological symptoms: randomised controlled trial.](#) Lancet; 363: 1491-502



Benign intracranial Hypertension

Diagnostic criteria

- = pseudotumor cerebri
- Most frequent cause of pulsatile tinnitus
- Obese (11-90%) women (2-8:1) with headache (94-99%),
- Blurry vision (48-68%) and pulsatile tinnitus (60%)
- Venous hum disappears on compressing ipsilateral jugular vein
- CT scan is normal (sometimes slit ventricles or empty sella)
- Papilledema
- LP > 20 cm H₂O
- Exclude endocrinological pathologies & evaluate medication use

Remark: some patients have LP < 20 cm water, no papilledema
(= idiopathic intracranial hypertension without papilledema in chronic daily headache)

Treatment recommendation

Weight loss, Lasix, Diamox, VP shunt

Literature

Meador KJ, Swift TR (1984) [Tinnitus from intracranial hypertension](#). Neurology. Sep;34(9):1258-61

Sismanis A (2003) [Pulsatile tinnitus](#). Otolaryngol Clin North Am. Apr;36(2):389-402, viii. Review



High Jugular Bulb

Diagnostic criteria

- Venous hum
- Jugular vein compression
- Bending over, reclining
- MRI CT angio

Treatment recommendation

- Ligation of the jugular vein
- Surgical jugular bulb lowering

Literature

- Lin DJ, Hsu CJ, Lin KN (1993) [The high jugular bulb: report of five cases and a review of the literature.](#) J Formos Med Assoc. Aug;92(8):745-50
- Muluk NB, Kara SA, Koç C (2005) [Relationship between tinnitus loudness level and internal jugular venous flow rate measured by coloured Doppler ultrasonography in patients with a high jugular bulb.](#) J Otolaryngol. Apr;34(2):140-6



Chiari

Diagnostic criteria

- 7-10% have tinnitus: non-pulsatile & pulsatile
- Sensorineural hearing loss (3%)
- Associated symptoms: occipital headache (70%), weakness (56%) and numbness (52%),
- torticollis, hypertension, heart rhythm disturbances, sleep apnea, hiccups, trouble swallowing,
- hemifacial spasm, trigeminal neuroalgia
- can be associated with basilar impression
- 100 % III-V prolongation
- 36 % I-III prolongation
- MRI

Pulsatile tinnitus

- Venous humm
- Cause = ICP / Hydrocephalus
- Worse on bending over
- Disappears on ipsilateral jugular -vene compression
- Hearing improves on jugular vene compression (masking)
- No BAEP changes

Non-Pulsatile tinnitus

- Intermittent
- BAEP changes in 75 %
- 100 % III-V prolongation
- 36 % I-III prolongation
- MRI

Treatment recommendation

Posterior fossa decompression

Literature

- Albers FW, Ingels KJ (1993) [Otoneurological manifestations in Chiari-I malformation](#). J Laryngol Otol. May;107(5):441-3
- Sperling NM, Franco RA Jr, Milhorat TH (2001) Otolologic manifestations of Chiari I malformation. Otol Neurotol. Sep;22(5):678-81
- Kumar A, Patni AH, Charbel F (2002) [The Chiari I malformation and the neurotologist](#). Otol Neurotol. Sep;23(5):727-35



Epilepsy

Diagnostic criteria

- Paroxysmal NP tinnitus as a isolated symptom or more frequently with disturbance of conciousness, progressive pitch, complex sounds
- Cortical irritative focus with EEG
- Video-EEG can demonstrate tinnitus coexistence with cortical temporal lobe discharges

Treatment recommendation

- Antiepileptic drugs (Level I)
- BZDs (Level I)

Literature

Eggermont JJ (2007) [Correlated neural activity as the driving force for functional changes in auditory cortex.](#) Hear Res. Jul;229(1-2):69-80

Cendes F et al (2005) [Familial temporal lobe epilepsy with auditory features.](#) Epilepsia. 46 Suppl 10:59-60

Gordon AG (2003) [Temporal lobe epilepsy and auditory symptoms.](#) JAMA. Nov 12;290(18):2407; author reply 2407

Microvascular compression

Diagnostic criteria

Symptoms associated with MVC n VIII – (VII)

1. Intermittent paroxysmal spells of unilateral tinnitus lasting only seconds
2. Associated ipsilateral symptoms
 - Facial nerve: cryptogenic or overt HFS
 - Intermediate nerve: otalgia with or without deep prosopalgia (geniculate neuralgia) or feeling of pressure in the ear
 - Vestibular nerve: vertiginous spells : short lasting, optokinetically induced
 - Cochlear nerve: frequency specific hearing loss
3. positive MRI for vascular compression
4. positive brainstem auditory evoked potential, using Moller's criteria

Typical evolution : spells more frequent, intermittent periods shorter, finally constant

Treatment recommendation

- If < 4 years, peak II absent, IPL I-III nl, no hearing loss: surgical decompression
- If vertebral artery, decompress
- If > 4 years poor results

Literature

- Møller MB, Møller AR et al (1993) [Vascular decompression surgery for severe tinnitus: selection criteria and results](#). Laryngoscope. Apr;103(4 Pt 1):421-7.
- De Ridder D (2007)
- Ryu et al (1998) [Neurovascular decompression of the eighth cranial nerve in patients with hemifacial spasm and incidental tinnitus: an alternative way to study tinnitus](#). Neurosurg. Feb;88(2):232-6
- Guevara N et al (2008) [Microvascular decompression of cochlear nerve for tinnitus incapacity: pre-surgical data, surgical analyses and long-term follow-up of 15 patients](#). Eur Arch Otorhinolaryngol. Apr;265(4):397-401

Classification

Possible CVCS : initially intermittent unilateral tinnitus spells without associated symptoms.

Probable CVCS : possible CVCS with high resolution heavily T2 weighted CISS images) or abnormal ABR

Definite CVCS associated symptoms (otalgia, vertigo or hemifacial spasms) or MRI demonstrating vascular compression of cochleovestibular nerve (using : probable CVCS with associated symptoms and/or abnormal ABR and/or abnormal MRI

Certain CVCS : definite CVCS which is surgically proven



Otosclerosis

Diagnostic criteria

- Presence of same disease in the family (30% cases)
- No signs of chronic otitis media (normal tympanic membrane, normal ET exploration, normal or hyper-pneumatized X Ray Schueller)
- Clearly negative RINNE test, WEBER towards affected side
- Conductive or combined hearing loss (Some cases of cochlear otosclerosis present sensorineural hearing loss)
- Loss of stapedius reflex
- Some cases require CT to rule out ossicular malformations or superior semicircular canal dehiscence
- some cases of cochlear otosclerosis require MRI to rule out acoustic neuroma

Treatment recommendation

- Wait and see, if mild hearing loss (Rinne positive)
- Stapedotomy / stapedectomy only to improve the hearing (improvement of Tinnitus unpredictable)
- Hearing aid fitting
- Tinnitus instrument (hearing aid + noise generator)

Literature

Evidence II-2:

Oliveira CA (2007) [How does stapes surgery influence severe disabling tinnitus in otosclerosis patients?](#)

Adv Otorhinolaryngol. 65:343-7

Evidence III:

Hildmann H (2006) [Middle Ear Surgery](#). Springer-Verlag



Middle Ear Dysplasia

Diagnostic criteria

- Clinical report of familiar cases
- Presence of other craniofacial malformations
- Otoscopy: Absence of tympanic membrane or malformation of the malleus, external ear malformation (stenosis or atresia of external ear canal)
- Tuning fork: negative RINNE test, WEBER towards the affected side
- Conductive or combined hearing loss
- CT scan to confirm the ossicle malformation
- MRI to rule out inner ear / VIII cranial nerve malformations
- Exploratory tympanotomy in selected cases

Treatment recommendation

- Surgery: Tympanoplasty, Plastic reconstruction of the outer ear
- Hearing aid fitting, consider implantable hearing aid
- BAHA
- CI

Literature

Yeakley JW et al (1996) [CT Evaluation of Congenital Aural Atresia: What the Radiologist and Surgeon Need to Know.](#) J Comput Assist Tomogr. Sep-Oct;20(5):724-31



Chronic and acute Otitis media

Diagnostic criteria

- Clinical report of recurrent ear infections
- Presence of effusion, otorrhea, adhesion or perforation of the tympanic membrane, tympanosclerosis, cholesteatoma in otoscopy
- Presence of signs of previous surgery (mastoid cavity, scars)
- Tuning fork testing: negative RINNE test, WEBER towards the affected side
- Conductive or combined hearing loss
- If no perforation of tympanic membrane, flat tympanogram?
- Nasopharyngoscopy: Mass? Adenoid tissue?
- CT scan of temporal bone, Schueller X Ray for extension of cholesteatoma and pneumatization of the mastoid bone

Treatment recommendation

- Acute treatment: antibiotics (local and systemic), Myringotomy with or without tube insertion
- Chronic: Antibiotics, Tympanic tubes, tympanoplasty, mastoidectomy
- Open hearing aid fitting. Risk of otorrhea
- BAHA, implantable hearing aids with round window application of the soundbridge

Literature

Hildmann H, Sudhoff H (2006) [Middle Ear Surgery](#). Springer-Verlag



Eustachian Tube dysfunction

Diagnostic criteria

- Clinical report of ear and respiratory infections
- Clinical report of nasal breath dysfunction
- Presence of effusion, adhesion or perforation of the ear drum in otoscopy
- Tuning fork: negative RINNE test, WEBER towards the affected side
- Conductive hearing loss
- Tympanometry towards negative or plain curves
- Eustachian tube examination altered.
- Nasopharyngoscopy, searching for mass or adenoid tissue
- CT or MRI scan in selected cases

Treatment recommendation

- Acute treatment: antibiotics, corticosteroids, antihistaminics, oximetazoline pseudoephedrine, mucolytics
- Surgery: Tympanic tubes (temporal, permanent/t-tube).
Some cases adenoidectomy, septum and turbinates surgery
- Hearing aid fitting.
- Training of tubal function (e.g. valsalva, blowing balloons)

Literature

Bluestone Ch (2005) [The Eustachian Tube](#). Elsevier

Alper C, Bluestone Ch (2004) [Advanced Therapies in Otitis Media](#). B C Decker



Ménière

Diagnostic criteria

Unilateral SN hypoacusia prevailing on the low frequencies or with a plateau, associated with a low frequency tinnitus which worsens while crisis. Feeling of auricular fullness and a gyratory vertigo during several hours accompanied by nausea, vomiting and sometimes diarrhea.

Treatment recommendation

Vertigo - Palliative medical treatment: 1st day of the crisis: 1 intra-venous injection of 40cc Hypertonic serum to 30%, followed by 2 injections of an amount every 6 hours.

2nd and 3rd days: 1 IV injection morning and evening + corticoid therapy: 1mg/Kg during 5 days + symptomatic treatment of the nausées+ Benzodiazepine.

Between crises :Betahistine 16 mg/j, and especially relaxation therapy.

In the event of instability, it's necessary to propose vestibular rehabilitation (VR) if the compensation is not completely realised.

Chemical intratympanic treatment: chemical destruction of the reached vestibule + VR

Curative surgical treatment: vestibular neurectomy + VR

Tinnitus: relieving, sound therapy – masking or MP3, sometimes - prosthesis for a less fluctuating deafness

Literature

Sajjadi H, Paparella MM (2008) [Meniere's disease](#). Lancet. Aug 2;372(9636):406-14

De Beer L, Stokroos R, Kingma H (2007) [Intratympanic gentamicin therapy for intractable Ménière's disease](#).

Acta Otolaryngol. 127(6): 605-612

Magnan J, Bremond G, Chays A, Gignac D, Florence A (1991) [Vestibular neurectomy by retrosigmoid approach: technique, indications, and results](#). Am J Otol. 12(2): 101-104



Endolymphatic hydrops

Diagnostic criteria

- Clinical report of unilateral or bilateral SN hearing loss prevailing on the low frequencies or with a plateau, associated with a low frequency tinnitus which worsens while crisis. Feeling of auricular fullness, sound hypersensitivity and recruitment.
- Audiometric findings of SN hearing loss
- OAE /DP can be useful in the initial stage of the disease, when the audiometry can be normal
- Electrocochleography and glycerol tests, can be useful too.

Treatment recommendation

- Oral, intravenous corticosteroids for acute debut or acute crisis of the disease
- Intratympanic corticosteroids when:
 - Severe or profound acute hearing loss
 - Many acute crisis that need systemic corticosteroids frequently (3 or 4 crisis /year)
 - No corticoid recommendation due to systemic diseases (diabetes, tuberculosis, immuno deficiencies..)
- Low salt diet + Increase water intake (2,5liters/day)
- Diuretics (hydrochlortiazide, acetazolamide)
- Betahistine, trimetazidine, piracetam
- Sound therapy – masking or MP3, sometimes - prosthesis for a less fluctuating deafness
- Glucosé hyper à 30%:IV 20 cc 3/J the first day
----- 1/J the 3 days after

Literature

- Garduño-Anaya MA et al (2005) [Dexamethasone inner ear perfusion by intratympanic injection in unilateral Ménière's disease: a two-year prospective, placebo-controlled, double-blind, randomized trial.](#) Otolaryngol Head Neck Surg. Aug;133(2):285-94. Level I.
- Selivanova OA et al (2005) [Intratympanic dexamethasone and hyaluronic acid in patients with low-frequency and Ménière's-associated sudden sensorineural hearing loss.](#) Otol Neurotol. Sep;26(5):890-5. Level III
- Junicho M et al (2008) [Prognosis of low-tone sudden deafness - does it inevitably progress to Meniere's disease?](#) Acta Otolaryngol. Mar; 128(3):304-8. Level II-2
- Naganuma H et al (2006) [Water may cure patients with Meniere disease.](#) Laryngoscope. 116(8):1455-60. Level I



Superior Canal Dehiscence

Diagnostic criteria

- Clinical findings: vertigo or oscillopsia induced by loud sound or changes in middle ear / intracranial pressure (Valsalva maneuver)
- Eye movements during vertigo typically align with the plane of the dehiscent SSC (vertical and torsional component)
- Conductive hearing loss, hyperacusis, autophony, tinnitus
- Tuning fork: WEBER towards the affected side
- Audiometry: air-bone gap, even with normal air conduction thresholds (bone conduction thresholds less than 0)
- Intact acoustic reflex responses
- Usually normal function in caloric testing
- VEMP (vestibular-evoked myogenic potentials): lower threshold for VEMP response
- High-resolution temporal bone CT scan (coronal view important)

Treatment recommendation

- Avoidance of the sound and pressure stimuli that cause symptoms
- Surgery: Resurfacing of superior canal through a middle fossa approach (III)
- Hearing aid fitting (Risk of vertigo when using the hearing aid)

Literature

Minor LB (2005) [Clinical manifestations of superior semicircular canal dehiscence.](#)

Laryngoscope 115:1717-1727

Banerjee A et al (2005) [Superior canal dehiscence: review of a new condition.](#)

Clin Otolaryngol 30, 9-15



N VIII tumor

Diagnostic criteria

- High pitched tinnitus (ringing or steam from a kettle)
- 60-85% of patients have tinnitus
- The smaller the tumor the more tinnitus
- Hearing loss (98%, 1-14% sudden)-desequilibrium (67%)-headache (32%)
- Facial numbness (29%) & weakness (10%)
- MRI, (BAEP)

Treatment recommendation

- Radiosurgery or microscopic surgery
 - 40 - 50% tinnitus disappears with surgery
 - 40-50% develop tinnitus
 - allmost no improvement with radiosurgery
- Wait & see

Literature

- Kanzaki J et al (1999) [Does hearing preservation surgery for acoustic neuromas affect tinnitus?](#) Skull Base Surg. 9(3):169-76
- Baguley (2005)



Acute Noise Trauma

Diagnostic criteria

- Notch in the audiometry typically at 3- 4 kHz
- DPOAE temporary or permanently disappeared at a specific frequency

Treatment recommendation:

- Avoidance of further noise trauma (III)
- Steroids (start within 3weeks), (systemic, transtympanic) (III)
- hyperbaric O2 (start within 6 weeks) (III)
- Antioxidants as treatment of acoustic trauma (III)
- Sound enrichment / hearing aid (III)

Literature:

Katz, Lippincott W & W (2009) Handbook of clinical audiology. Chap. 31



Chronic sensorineural hearing loss

Diagnostic criteria

Audiometry, Progressive, bilateral, sensorineural or mixed hearing loss

Treatment recommendation

- No causal treatment of hearing loss possible,
- Hearing Aids (Level II-2)
- Cochlear Implant (Level II-2)

Literature

Evidence level III:

Del Bo L, Ambrosetti U (2007) [Hearing aids for the treatment of tinnitus.](#) Progress in Brain Research 166:341-5

Evidence level II 2:

Vermeire K, Van de Heyning P (2009) [Binaural Hearing after Cochlear Implantation in Subjects with Unilateral Sensorineural Deafness and Tinnitus.](#) Audiol Neurootol. 14(3):163-71



Acute hearing loss

Diagnostic criteria

Acute, unilateral, sensorineural hearing loss

Differential diagnosis

- viral or vascular attacks, neuroma, beginning Ménière,
- Sound traumatism, cochlear barotraumatism, fracture of the temporal bone

Therapeutic recommendation: urgency !

- Hyperbaric oxygen-therapy + vasodilators + corticoids
- Carbogen Inhalation
- Perfusion of vasodilators and corticoids
- Intratympanic corticosteroids as a rescue treatment after systemic
- corticosteroids or as the initial treatment
- Surgical exploration?

Literature:

- Lee H, Baloh RW (2005) [Sudden deafness in vertebrobasilar ischemia: clinical features, vascular topographical patterns and long-term outcome.](#) J Neurol Sci. Jan 15;228(1):99-104
- Hamid M, Trune D (2008) [Issues, indications, and controversies regarding intratympanic steroid perfusion.](#) Curr Opin Otolaryngol Head Neck Surg. Oct;16(5):434-40
- Haynes DS et al (2007) [Intratympanic dexamethasone for sudden sensorineural hearing loss after failure of systemic therapy.](#) Laryngoscope. Jan;117(1):3-15. Review.
- Plaza G, Herraiz C (2007) [Intratympanic steroids for treatment of sudden hearing loss after failure of intravenous therapy.](#) Otolaryngol Head Neck Surg. Jul;137(1):74-8
- Zivić L, Zivić D, Stojanović S (2008) [Sudden hearing loss--our experience in treatment with vasoactive therapy][Article in Serbian]. Srp Arh Celok Lek. Mar-Apr;136(3-4):91-4. Links
- Psillas G, Pavlidis P, Karvelis I, Kekes G, Vital V, Constantinidis J (2008) [Potential efficacy of early treatment of acute acoustic trauma with steroids and piracetam after gunshot noise.](#) Eur Arch Otorhinolaryngol. Dec;265(12):1465-9
- Mösgeles R et al (2008) [Rheopheresis for idiopathic sudden hearing loss: results from a large prospective, multicenter, randomized, controlled clinical trial.](#) Eur Arch Otorhinolaryngol. Oct 16



Space occupying lesion (SOL)

Diagnostic criteria

- Tinnitus: non-pulsatile or venous hum
- Hearing loss, disequilibrium, other cranial nerve related symptoms
- ICP increase: Headache (morning, valsalva) , nausea, vomiting, papiledema
- Space occupying lesion in the MRI

Treatment recommendation

- Surgical removal
- Biopsy +gamma knife or chemo+/- XR-therapy
- Marsupialisation if arachnoid cyst

Level II-3

Literature

Depression

Diagnostic criteria / characteristic features

- Depressed mood, reduction of energy, activity, interest, concentration, self-esteem- and self confidence
- No changes from day to day or due to circumstances
- psychomotor retardation, agitation, loss of appetite, weight loss, and loss of libido
- Sleep disturbances
- Suicidality is a frequent symptom of depression and needs always to be specifically addressed (> see slide suicidality)
- Duration of 2 weeks or more

Treatment recommendation

- Pharmacotherapy with standard antidepressants (Evidence Level I)
- Choice of antidepressants according to symptomatology and comorbidity (Evidence Level I)
- Newer antidepressants have lower risk of pharmacological interactions, especially important in older patients with polypharmacy (Evidence Level I)
- If loss of energy, activity and interest are main symptoms, first choice may be SSRIs (e.g. citalopram, sertraline) or dual acting drugs (Venlafaxine, duloxetine)
- Comorbid sleep disturbances or agitation: first choice may be mirtazapine or tricyclics (e.g. amitriptyline, trimipramine)
- Comorbid pain syndromes: amitriptyline, mirtazapine, venlafaxine, duloxetine (Evidence Level I)
- At least 4 weeks treatment at sufficiently high daily dosages depending on tolerance (Evidence Level I)
- Psychotherapy (cognitive behavioral therapy), sociotherapy, special therapies (Evidence Level I)



Anx. Disorder

Diagnostic criteria / characteristic features

The sufferer must have primary symptoms of anxiety most days for at least several weeks at a time, and usually for several months. These symptoms should usually involve elements of:

- apprehension (worries about future misfortunes, feeling "on edge", difficulty in concentrating, etc.);
 - motor tension (restless fidgeting, tension headaches, trembling, inability to relax); and
 - autonomic overactivity (lightheadedness, sweating, tachycardia or tachypnoea, epigastric discomfort, dizziness, dry mouth, etc.).
- The ICD-10 Classification of Mental and Behavioural Disorders, World Health Organization, Geneva, 1992

Treatment recommendation

Non-pharmacologic

- Cognitive behavioral therapy (Evidene Level I)

Pharmacotherapy

- SSRIs (e.g. Citalopram, paroxetine, sertraline) (Evidene Level I)
- Pregabalin (pregabalin especially in patients with comorbid sleep disturbances reasonable) (Evidene Level I)

At least 4 weeks treatment at sufficiently daily high dosages depending on tolerance



Insomnia

Diagnostic criteria

Suffering from sleep problems (falling asleep or maintaining sleep) with impact on daytime functioning

Treatment recommendation

Non-pharmacologic

- “Sleep hygiene” (e.g. regular bed-times (including weekends), bedtime restriction;
- avoiding stimulating substances like caffeine, nicotine, alcohol or heavy meals; comfortable temperature;
- Sound enrichment (e.g. gentle music)
- Cognitive behavioural therapy with special focus on tinnitus and sleep¹

Pharmacologic

- Benzodiazepineagonists (e.g. Zopiclon 7,5 mg, Zolpidem 10 mg) (avoid regular long-term treatment if possible)(Evidence level I)
- antidepressants e.g. amitriptylin (25-50 mg), trimipramine (50-100 mg), mirtazapine (7.5 – 15 mg) (Evidence level I)
- pregabalin (25-150 mg at night) (evidence Level I for improvement of sleep in fibromyalgia patients)

Literature

Crönlein T, Langguth B, Geisler P, Hajak G (2007) [Tinnitus and Insomnia](#). Progress in Brain Research 166:227-33

Hebert and Carrier (2007) [Sleep complaints in elderly tinnitus patients: a controlled study](#). Ear Hear. 28(5):649-55



Somatoform disorder

Diagnostic criteria

- Multiple unspecific somatic symptoms without physical basis;
- persistent requests for medical investigations;
- if somatic disorders are present, they do not explain the nature and extent of the symptoms
- Comorbidity with other psychiatric diseases (e.g. depression) is common
- Duration of 2 years or longer

Screening question

Have you had **many** physical complaints not clearly related to a specific disease

Treatment recommendation

Non-pharmacologic

Psychoeducation; cognitive behavioural therapy (Evidence Level II-2)

Pharmacologic

According to psychiatric comorbidity (anxiety, depression) or other comorbidity (e.g. fibromyalgia)

Antidepressiva may be helpful¹(Evidence Level III)

Literature

¹ O'Malley et al (1999) J Fam Pract 48: 1146-1149



Tinnitus associated with cervical pathology

Diagnostic criteria

1. Myofascial trigger point
2. Muscular tension and/or tender points
3. Vertebrae fusion or rotation
4. Muscular or joint dysfunction

Treatment recommendation

1. Deactivation of myofascial trigger / tender points (manual, infiltration, or acupuncture) (evidence level III)
2. Other options (not directed to trigger points):
 - manual cervical therapy (evidence level III)
 - infiltration of the afferencies in the neck (evidence level III)
 - trans-electrical nerve stimulation (evidence level III)
 - Tai Chi or Gi Cong (evidence level III)

Literature

Estola-Partanen M (2000) [Muscular Tension and Tinnitus](#). Dissertation. Tampere: Faculty of Medicine, University of Tampere

Kaute BB (1998) [The influence of atlas therapy on tinnitus](#). Int Tinnitus J. 4(2):165-167

Björne A (2007) [Assessment of temporomandibular and cervical spine disorders in tinnitus patients](#). Prog Brain Res. 166:215-9

Herraiz et al (2007) [Trans-electrical Nerve Stimulation \(TENS\) for somatic tinnitus](#). PBR

Biesinger E, Reissauer A, Mazurek B (2008) [[The role of the cervical spine and the craniomandibular system in the pathogenesis of tinnitus. Somatosensory tinnitus](#)][Article in German]. HNO. 56(7):673-7



Diagnostic criteria

- TMJ dysfunction diagnosed by a specialist
- Modulation of tinnitus by temporomandibular maneuvers

Treatment recommendation

- Infiltration of muscles with trigger points (evidence level III)
- Orofacial myofascial therapy (evidence level III)
- TENS (evidence level III)
- Acupuncture (evidence level III)
- Oral rehabilitation (splint) (evidence level III)
- Surgery (evidence level III)
- Biofeedback (evidence level III)

Literature

de Felício CM, Melchior Mde O, Ferreira CL, Da Silva MA (2008) [Otologic symptoms of temporomandibular disorder and effect of orofacial myofunctional therapy.](#) Cranio.

Apr;26(2):118-25

Erlandsson SI et al (1991) [Tinnitus: evaluation of biofeedback and stomatognathic treatment.](#) Br J Audiol. Jun;25(3):151-61

Björne A (2007) [Assessment of temporomandibular and cervical spine disorders in tinnitus patients.](#) Prog Brain Res. 166:215-9



Symptomatic Treatment

Definition

The term symptomatic treatment describes treatment options, which are indicated irrespective of the exact tinnitus etiology and which aim to reduce tinnitus perception and tinnitus related distress

Indication

In case of an identified underlying pathology and available causal treatment this treatment approach should have first priority. Independently of any potential causal treatment, symptomatic treatment should always be considered.

Symptomatic treatment is especially indicated, when specific treatments (as described in the blue section) are not possible or do not result in sufficient relief.

Combination of treatments

Frequently a combination of different treatment strategies leads to best results. In case that synergistic effects of different treatment strategies are known (e.g. auditory stimulation + cognitive behavioural therapy), this is mentioned.



Indication / contraindication

Counselling should occur at many stages in the treatment process, by many professionals.

Counselling is the process of informing, advising and empowering individuals with a need for support.

The following aspects should be considered:

Patients may have developed inappropriate ways of thinking about tinnitus.

Bothersome tinnitus may be a failure to habituate or a failure to shift attention away from tinnitus.

Learning mechanisms may be involved in the response to tinnitus

Literature:

Tyler RS (2005) [Psychological frameworks for considering tinnitus treatment. Tinnitus Treatment](#). Thieme

Description of treatment

Counselling can be psycho-education (Informational counseling) and/or CBT based, depending on training of the professional

Basis: Education/information alone contribute to reduce distress

Client-centered

A client centered approach is used with greater discussion of those areas important to the tinnitus sufferer. The clinician must assess the level of understanding and needs of the patient and adjust their counseling appropriately (*e.g slides ▶ [83](#), ▶ [84](#)*).

Directive counselling

Structured counselling sessions aim to achieve reclassification of tinnitus into a category of neutral signal. Tinnitus is demystified and patients are taught about physiological mechanisms of tinnitus and its distress, as well as the mechanisms through which tinnitus habituation can be achieved (*e.g slides ▶ [83](#), ▶ [84](#)*).

Counselling - One suggested method

An overview of a typical CBT package for tinnitus.

Modified version from Andersson (2002)

Information regarding tinnitus and explanation of probable causes

Functional analysis of influencing factors on tinnitus annoyance

Advice regarding hearing loss and its possible remedies

Use of environmental sound enrichment strategies

Relaxation training

Cognitive restructuring of thoughts and beliefs

Emotional reactions are focused upon, especially fear and avoidance in relation to tinnitus

Advice regarding problems with concentration and methods of improvement

Advice regarding sleep hygiene for those with sleeping difficulties

Relapse prevention advice

Counselling - One suggested method

Explanation of auditory system, tinnitus and habituation

Complete version structured on the anatomy and physiology of auditory pathways:

1. outer and middle ear, as responsible for conduction and amplification of sounds to the inner ear
2. Eustachian tube, as a source of repetitive sounds during swallowing, which are usually filtered by the central auditory pathways, although they are normally louder than the own tinnitus.
3. inner ear: hair cells and possible pathologies (noise trauma, ototoxicity, ageing, etc)
4. nerve: conducting stimuli from periphery to central, possibility of acoustic neuroma (very careful to avoid increasing fear and awareness)
5. brainstem: reaction to sound when detecting danger or an unidentifiable source and provoking a strong and subconscious reaction: anxiety, muscular tension, sleep and concentration problems, inability to externalise sound, etc. Tinnitus as a new signal to the brain creating arousal, fear, threaten-oriented reaction. Hyperactivity plus anxiety / depression become chronic, originating also the hyperacusis
6. Midbrain: add emotions to the sound depending on the subconscious evaluation, focusing even more in the tinnitus sound. Ex: cricket outside and inside the brain, mother and child, good / bad neighbour cutting grass

Explain that habituation means reducing tinnitus towards a harmless cricket; importance of having sound enrichment as soon as possible (through different ways) to avoid neuroplasticity; increase hope in the treatment, whichever the option is (explanation of therapeutic steps tailored to each one);



Auditory Stimulation

Also known as Acoustic Therapy or sound therapy

Aim: use of external sound(s) to provide relief from tinnitus via masking or habituation. Sound therapy can also induce neurophysiological functional changes in the deafferented auditory pathways.
For all patients whom surgical or medical treatment is impossible or has been unsuccessful or wish to avoid such intervention.

Contraindications: Lack of motivation of the patient. Not indicated in patients with severe depressive illness or high suicidality

The auditory stimulation can be divided in two groups as follows.

▶ Passive auditory stimulation

Goals are:

- reducing the attention drawn to the tinnitus, induce habituation,
- reducing the perceived loudness of the tinnitus,
- induce brain plastic changes in deafferented neural areas.

Includes:

compensation for hearing loss, total or partial masking, music therapy, habituation and desensitisation approaches. These techniques can be used in conjunction or alone.

Sounds used:

nature or therapeutical customized sounds or electrical stimulation in the case of cochlear implant

Devices:

hearing aids and cochlear implants, sound generators, combination instruments (sound generator with hearing aid), MP3 players, music and custom sound generators.

▶ Active auditory stimulation and training

Goals are:

sound is used in listening tasks to divert attention from tinnitus and/or lead to reduced representation of tinnitus within central auditory pathways

Involves cognitive processing of sound

Includes:

- discrimination tasks;
- categorisation tasks
- selective attention
- virtual reality multimodal training

Passive Auditory Stimulation

The passive auditory stimulation can be considered a well established treatment for providing replicable long-term reduction of tinnitus impact in terms of annoyance and quality of life. However most studies show Evidence Level II and III

► Masking

Evidence Level II-1

HENRY J. A. ; SCHECHTER M. A. ; ZAUGG T. L. ; GRIEST S. ; JASTREBOFF P. J. ; Verno J. A. ; KAELIN C. ; MEIKLE M. B. ; LYON K. S. ; STEWART B. J. (2006) [Clinical trial to compare tinnitus masking and tinnitus retraining therapy](#). Acta Otolaryngol Suppl. Dec;(556):64-9

Immediate relief from tinnitus-high tinnitus severity

► Habituation with: sound stimulation at mixing point and/or environmental device

Evidence Level II-3

HENRY J.A., ZAUGG T.L., MYERS P.J., SCHECHTER M.A. (2008) [Using therapeutic sound with progressive audiologic tinnitus management](#). Trends Amplif.;12(3):188-209

► Habituation with: music

Evidence Level I

DAVIS P.B., PAKI B., HANLEY P.J. (2007) [Neuromonics Tinnitus Treatment: third clinical trial](#). Ear Hear. 28(2):242-59.

Medium time relief from tinnitus (low, medium and high severity) not associated with hearing loss

► Hearing compensation for: 1) habituation, 2) elicit auditory neural plasticity and reprogramming

Evidence Level III:

Del Bo L., AMBROSETTI U. (2007) [Hearing aids for the treatment of tinnitus](#). Progress in Brain Research 166. Tinnitus: Pathophysiology and Treatment. Elsevier

Evidence Level II-2:

VERMEIRE K., VAN de HEYNING P. (2008) [Binaural Hearing after Cochlear Implantation in Subjects with Unilateral Sensorineural Deafness and Tinnitus](#). Audiol Neurootol. 13;14(3):163-171.

Medium time relief from tinnitus (low, medium and high severity) associated with hearing loss (i.e. SN, Meniere, sudden hearing loss, presbioacusys, conductive)

Passive Auditory Stimulation Masking

Indication

For patients whom surgical or medical treatment isn't possible or has been unsuccessful or wish to avoid such intervention

Immediate relief from tinnitus

Contraindication

Not indicated in patients with severe depressive illness or high suicidality

High levels of masking sound requested in some cases

Severe hearing loss

Discomfort or adverse reaction to sound (hyperacusis or reduce sound tolerance)

Description of treatment

Can be used in conjunction with hearing compensation or alone in case of normal hearing level. Sound used to mask the tinnitus, for this reason the masking produce a sense of immediate relief from the annoyance caused by tinnitus

Uses whatever type of sound that produces the greatest relief

Accomplished by :

Total masking = Covering up tinnitus sound

Partial masking = Changing the sound of tinnitus by reducing the perceived loudness

Recommend lowest level masker that provides adequate relief

Instrumentation:

Wearable ear-level devices, Hearing aids, sound generators, combination aid [hearing aid + masker], Non-wearable devices (to enrich sound environment), Tabletop devices (eg. water fountains, sound machines), Pillow speakers.

Passive Auditory Stimulation Habituation

Indication

For all patients whom surgical or medical treatment isn't possible or has been unsuccessful or wish to avoid such intervention. Relief from tinnitus because induce habituation to the tinnitus perception

Contraindication

Not indicated in patients with severe depressive illness or high suicidality
Low motivation people - expectations of quick or immediate relief
Unwilling to use sound for 8 hours or greater per day
Severe hearing loss (cochlear implant aside)

Description of treatment

Can be used in conjunction with hearing compensation or alone in case of normal hearing level
Sound and counselling used to produce an enduring sense of reduced tinnitus after ceasation of sound (e.g. TRT)
Decline in response to familiar auditory stimuli (tinnitus) due to repeated exposure.
Attention and emotional defocusing of tinnitus.
Recommend lowest level sound that reduces tinnitus detectability (TRT suggests "Mixing point" - blending of tinnitus and therapeutic sound").
Uses whatever type of sound that produces the greatest relief, often broadband sound

Instrumentation:

Wearable ear-level devices, Hearing aids, sound generators, combination aid [hearing aid + masker], Non-wearable devices (to enrich sound environment), Tabletop devices (eg. water fountains, sound machines), Pillow speakers.

Passive Auditory Stimulation Music

Indication

For patients whom surgical or medical treatment has been unsuccessful or wish to avoid such intervention
Better than moderate hearing loss
High levels of stress, need for relaxation
Desire immediate relief from tinnitus

Contraindication

Not indicated in patients with severe depressive illness or high suicidality
Moderate or severe hearing loss

Description of treatment

Music used to produce a sense of relief from the annoyance caused by tinnitus through masking or habituation
Music has positive effect on emotion, mood, stress & anxiety
Suppress negative reactions and associations caused by tinnitus
Accomplished by: Music therapy, self selected music, custom music

Instrumentation:

Radio, digital music players (MP3, ipod), CD, live music, commercial tinnitus instruments (e.g Neuromonics)

Passive Auditory Stimulation

Hearing compensation

Indication

For patients with aidable (hearing aids or cochlear implant) hearing loss. The aim is to use of external sound(s) to provide relief from tinnitus via masking or habituation. Hearing compensation could also induce neurophysiological functional changes in the deafferented auditory pathways (even if not already completely proof)

Contraindication

Not indicated in patients with severe depressive illness or high suicidality.
Normal hearing or Hearing loss and tinnitus above 6 kHz.
Severe hyperacusis.

Description of treatment

Normalisation of auditory activity through prosthetic correction of hearing loss for full access to masking, habituation, auditory neural path regeneration, and all other sound therapeutical approaches.
Amplified environmental sound used to produce a sense of relief from the annoyance caused by tinnitus.
Amplified sound results in masking or tinnitus habituation.

Instrumentation:

Hearing aids appropriate for individual's hearing loss (flexible programming characteristics, multichannel adjustment of gain, output and compression, open fitting where appropriate) and amplification of environmental sounds (ability to turn off expansion & noise reduction, low compression thresholds).
Combination instruments for intrusive tinnitus where hearing aids alone are ineffective.
Cochlear implants when hearing loss is too great to benefit from hearing aids.
CROS aids in the presence of unilateral "dead ears".



Auditory Stimulation: PERCEPTUAL (Active) TRAINING

Perceptual training for tinnitus can be considered an emerging treatment for tinnitus treatment. Most studies are preliminary small scale experimental studies.

Frequency Discrimination training

Evidence Level II-3

FLOR H. ; HOFFMANN D. ; STRUVE M. ; DIESCH E (2004) [Auditory Discrimination Training for the Treatment of Tinnitus](#). Applied Psychophysiology and Biofeedback, 29 (2), 113-120.

HERRAIZ C. ; DIGES I. ; COBO P. ; PLAZA G.; APARICIO J. M .(2006) [Auditory discrimination therapy \(ADT\) for tinnitus management: preliminary results](#). Acta Otolaryngol Suppl. 556, 80-3.

Diversion of attention from tinnitus to everyday sounds

Evidence Level II-3

SEARCHFIELD G. D. ; MORRISON-LOW J. ; WISE K. (2007) [Object identification and attention training for treating tinnitus](#). Prog Brain Res. 166, 441-60.

Virtual reality

Cognitive restructuring through representation of tinnitus as a visual and auditory avatar that can be manipulated by interaction in a virtual environment.

Categorisation training



Cognitive behavioural Therapy

Indication / contraindication

Motivation of the patient

More indicated in decompensated tinnitus

Not indicated in patients with high suicidality, clinically relevant cognitive deficits or language problems

Description of treatment

Aim of the therapy is the analysis and modification of disturbances induced by the tinnitus.

Dysfunctional cognitions and / or behaviour will be analysed and modified.

Coping strategies will be enhanced.

Informations about tinnitus (mechanisms, course etc.) will be provided (“Counselling”).

Tinnitus perception will be modified (“Retraining”).

Evidence level

Significant Improvement in Quality of life by CBT (Evidence Level I)

No improvement in Tinnitus loudness / depressive symptoms

Literature

Martinez Devesa et al (2007) [Cognitive behavioural therapy for tinnitus](#). Cochrane Database Syst Rev. Jan 24;(1):CD005233



Pharmacotherapy

No pharmacologic treatment can yet be considered well established in terms of providing replicable long-term reduction of tinnitus impact, in excess of placebo effects (*Dobie RA et al (1999) [A review of randomized clinical trials in tinnitus. Laryngoscope 109:1202-1211](#)*)

However for specific subgroups of tinnitus, specific drugs have shown some efficacy (most studies Evidence Level II)

- High Tinnitus severity
- Comorbidity with depression

Antidepressants, e.g. sertralin, nortriptyline, amitriptyline

Evidence Level II-2

Zöger S et al (2006) [J Clin Psychopharmacol;26:32-39](#)

Sullivan M et al (1993) [Arch Int Med 153:2251-2259](#)

Bayar N et al (2001) [J Otolaryngol 30:300-303](#)

- auditory nerve vascular compression
- myoklonus tinnitus

Carbamazepine

Evidence Level II-2

Mardini (1987) [N Eng J Med 317:1524](#)

Brandt and Dietrich (1994) [Baillieres Clin Neurol 3:565-575](#)

Levine RA (2006) [ORL J Otorhinolaryngol Relat Spec 68:43-46](#)

Rahko and Häkkinen (1979) [J Laryngol Otol 93:123-127](#)

- decompensated tinnitus (indication careful, due to risk of dependency)

Benzodiazepines, e.g. alprazolam, clonazepam

Evidence Level II-3

Johnson et al (1993) [Arch Otolaryngol Head Neck Surg 119\(8\):842-845](#)

Lechtenberg and Shulman. (1984) [Arch Neurol 41:718-721](#)

Ganancia MM et al (2002) [Int Tin J 8:50-53](#)

- Menière's disease

Intratympanic Dexamethasone

Evidence Level I:

Garduno-Anaya MA (2005) [Otolaryngol Head Neck Surg. Aug;133\(2\):285-94](#)

- tinnitus, associated with chronic noise trauma

Acamprosate

Evidence Level I

[Aazevedo AA and Figureido RR \(2005\)](#)

- benign intracranial hypertension

Furosemide Acetazolamide

Evidence Level II-3

[Sismanis et al \(1990\)](#)

- sudden hearing loss

Intratympanic Dexamethasone

Evidence Level II-3:

[Haynes et al \(2007\)](#)



Acute Treatment

Cortisone
 IV: 250mg prednisolone once a day, for 3 days
 To discuss:
 - Oral
 - Local: whenever IV is counterindicated (diabetics, children, etc)
 - Hemorheological agents (oral or IV)

Auditory stimulation / environmental sound

Recommendation based on animal data, no data in humans yet

Cervical/TMJ treatment

 Indications:
 - Children
 - Trauma/pain/manipulation of head and neck
 - Abnormalities in cervical examination (pain, limitation of movements, tinnitus modulation, etc)

 Options:
 - Manual therapy
 - Physiotherapy
 - Osteopathy
 - Infiltration

Hyperbaric chamber
 1 à 2 meetings by day during 5 or 10 Days with cocktail IV(corticoids, Vasodilators...) and inhalation O2 under pressure at 1.5 Bar

 Evidence in acute tinnitus with sudden hearing loss: yes
 Evidence in acute tinnitus without hearing loss: no

Evidence level / Literature:

Topuz E, Yigit O, Cinar U, Seven H. (2004) [Should hyperbaric oxygen be added to treatment in idiopathic sudden sensorineural hearing loss?](#) Eur Arch Otorhinolaryngol. Aug;261(7):393-6
 Domachevsky L, Keynan Y, Shupak A, Adir Y (2007) [Hyperbaric oxygen in the treatment of sudden deafness.](#) Eur Arch Otorhinolaryngol. Aug;264(8):951-3
 Böhmer D (1997) [Treating Tinnitus with Hyperbaric Oxygenation.](#) Int Tinnitus J. 3(2):137-140



Neuromodulation

Tinnitus suppression by single sessions of rTMS

yes

Epidural stimulation with implanted electrodes

Evidence Level II-2

De Ridder et al (2007)
[Acta Neurochir Suppl. 97\(Pt 2\):451-62](#)

10 days of 1 Hz rTMS over the left temporal or temporoparietal cortex

Better results in patients with:
- better hearing
- shorter tinnitus duration

Evidence Level I
(short term efficiency)

Langguth et al (2008)
[Brain Stimulation 1\(3\):192-205](#)

Neurofeedback

Evidence Level I
(short term efficiency)

Dohrmann et al (2007)
[Restor Neurol Neurosci. 25\(3-4\):371-8](#)

Epidural stimulation

Indication :

severe tinnitus (grade III / IV)

Treatment resistance to noninvasive treatment strategies

Unilateral pure tone tinnitus,

tinnitus suppression by single sessions of rTMS

Contraindication:

epilepsy, cardiac pace-maker, need for frequent MRI scans (e.g. follow-up of tumor)

personality disorder, pregnancy

Description of treatment

In case of transient suppression of the tinnitus by rTMS presentation of the tinnitus tone in fMRI for exact localisation of the representation of the tinnitus frequency in the secondary auditory cortex.

Neuronavigation guided implantation of the epidural electrode over this area; in case of positive test stimulation, implantation of a stimulus generator abdominally. Optimization of the stimulation parameters over the following weeks.

Evidence level: II-2

Literature:

De Ridder D et al (2007) [Auditory cortex stimulation for tinnitus](#). Acta Neurochir Suppl. 97(Pt 2):451-62.



Transcranial magnetic stimulation

Indication

Preferable tinnitus of shorter duration (< 4 years) and with normal hearing

Contraindication

Mechanical or electrical implants, cardiac pace maker, epilepsy, pregnancy

Description of treatment:

10 sessions of rTMS over the left temporal or left temporoparietal cortex within two weeks

Evidence level: I (for short term efficacy)

Literature:

Langguth et al (2008) [Controversy: Does repetitive transcranial magnetic stimulation/transcranial direct current stimulation show efficacy in treating tinnitus patients?](#)

Brain Stimulation 1(3):192-205



Neurobiofeedback

Indication :

Motivation to do at least 10 sessions of neurobiofeedbacktherapy

Contraindication:

Description of treatment:

Assessment of ratio between alpha and delta spectral power in the EEG;
Neurofeedback with the goal to increase alpha and reduce delta

Evidence level: I (for short term efficacy)

Literature:

Dohrmann et al (2007) [Tuning the tinnitus percept by modification of synchronous brain activity](#). Restor Neurol Neurosci. 25(3-4):371-8



VEMPs (following tinnitus constant + vertigo)

Indication

Vestibular evoked myogenic potential test (VEMPs) is indicated in all tinnitus patients with dizziness or imbalance disorders, and all those with vertigo under the presence of intense sound stimulation.

Short description

Brief loud monoaural clicks or tone-bursts produce a large inhibitory potential in the tonically contracting ipsilateral sternocleidomastoid muscle, even in profound sensorineural hearing loss. This potential is generated by synchronous discharges of muscle cells through stimulation of the saccule and transmission via the ipsilateral medial vestibulospinal tract to the sternomastoid motoneurons. VEMPs tests the function of the saccule, superior and lateral semicircular canals (SCC).

Diagnostic value

- Superior semicircular dehiscence (lower threshold and large amplitude VEMPs)
- Ménière's Disease diagnosis and they can be used to monitor intratympanic gentamicin
- Vestibular neuritis and Superior SCC benign paroxysmal positioning vertigo.
- Vestibular schwannoma, multiple esclerosis.

Literature

Halmagy GM et al (1995) [Tapping the head activates the vestibular system: a new use for the clinical reflex hammer.](#) Neurology. 45:1927-9

Kushiro K et al (1999) [Saccular and utricular inputs to sternocleidomastoid motoneurons of decerebrate cats.](#) Exp Brain Res. Jun;126:410-6

Streubel SO (2001) [Vestibular-evoked myogenic potentials in the diagnosis of superior canal dehiscence syndrome.](#) Acta Otolaryngol Suppl (Stockh) 545:41-9



Cran. + cerv. CT / MRI (following trauma)

Indication and short description

- X-ray of the neck, eventually with flexion and extension
- Cran. CT / MRI in tinnitus after ear, neck (whiplash) or head trauma
- Cerv. CT / MRI + MR Angio in tinnitus after neck trauma (whiplash)
- CT for detection of bony lesion
- **In case of neck trauma, CT / MRI before functional neck exam !**

Diagnostic value

- bone lesions (spine, scull, petrous bone, craniocervical junction, ossicular chain, TMJ)
- cerebral lesions (e.g. contusions, bleeding, ischemia, e.g. due to carotid dissection)
- nerve compression / dissection
- carotid or vertebral dissection

Literature

BAEP (in posttraumatic tinnitus)

Indication

- screening tool for acoustic nerve pathology, in case that MRI is not available
- Functional assessment of auditory pathways up to inferior colliculus

Short description

BAEP at high intensities while identifying the first 5 waves of the Brain Stem, the variations of inter-waves and inter-auricular conduction, appreciation of the correlation between the objective thresholds to the CLICK and the data of the tonal audiogram.

Diagnostic value

If absent or pathologic, suspicion of structural or functional deficit in the auditory pathways such as cochlear damage, traumatic hearing loss or nerve compression or dissection (CT / MRI should be performed)

EEG (in posttraumatic tinnitus)

Indication

After head trauma

Short description

Standard EEG, eventually with provocation (flashlight, hyperventilation)

Diagnostic value

- Irritative focus in temporal or temporal with secondary generalization
- Video-EEG demonstrative if tinnitus coexists with temporal lobe discharges

Literature

Eggermont JJ (2007) [Correlated neural activity as the driving force for functional changes in auditory cortex.](#) Hear Res. Jul;229(1-2):69-80

Cendes F et al (2005) [Familial temporal lobe epilepsy with auditory features.](#) Epilepsia, 46, suppl 10

Gordon AG (2003) [Temporal lobe epilepsy and auditory symptoms.](#) JAMA. Nov 12;290(18):2407; author reply 2407



Echo-Doppler

Indication

Tinnitus after neck trauma

especially if there are further symptoms for carotid or vertebral dissection such as unilateral neck pain or headache, face numbness, Horner's syndrome, transitory ischemic attacks etc.

Short description

Echo- Doppler of neck vessels. Measurement of flows, resistances and thickness of the Intima. Search for dissection of the vessel

Diagnostic value

Proof or exclusion of neck vessel dissections

Neck exam (in posttraumatic tinnitus)

Indication

Tinnitus after neck trauma (whiplash)

Cave: before a functional neck exam a dissection of neck vessels and a cervical neck fractures / dislocation has to be excluded

Short description

Inspection, palpation of the neck

Passive and active antero-, postero- and lateroflexion of the neck

Turning of the neck

Diagnostic value

Functional or structural disorders (e.g. muscle tension abnormalities)

Differential indication for physical therapy

Literature

Psych Exam (in posttraumatic tinnitus)

Indication

Tinnitus associated with emotional trauma

Short description

Psychiatric interview

Psychometric evaluation if necessary

Cave: Careful exploration, exploration of the traumatic event is not necessary and should be better avoided,

Diagnostic value

Diagnosis of posttraumatic stress disorder

Literature